

Human teeth from Nemrik

Krystyna Szlachetko, Małgorzata Zadurska

Department of Orthodontics
Medical University of Warsaw, Poland

Between 1985 and 1987 a team of Polish archaeologists directed by Prof. Stefan Kozłowski, the head of the Department of Mediterranean Archaeology of the Warsaw University, carried out excavations in the south of Kurdish Plateau in Iraq, at Nemrik. We were commissioned to study the human teeth from this site.

The material is dated to the Pre-Pottery Neolithic period. It includes 721 quite well preserved teeth of which 685 were permanent teeth and 36 deciduous ones. The specification of permanent teeth is presented in **Table 1** and of deciduous teeth – in **Table 2**. Those teeth are at different stages of development: permanent teeth – from crown's germ to completely formed ones with obliterated root canals; deciduous teeth – from crown's germ to completely formed ones with marks of different extent of root resorption. Some teeth are fixed in fragments of maxillae or of mandibles, small fragments of both jaws do not contain teeth lost after death, in others – fragments of roots were discovered only thanks to radiological examination. A few fragments of bones held together by soil were left in this state because of the fragility of the material. Moreover, we found plenty of very small fragments of crowns and roots of deciduous and permanent teeth which were impossible to identify.

In odontoscopic examination, morphology of crowns and roots of teeth was taken into account to determine variability, deviation from the normal structure and possible pathology. In general the examined material was very fragile. In many cases fractures of enamel and crowns of different extent are visible, which often made tooth identification difficult. Roots are even more damaged, sometimes along their whole length.

Overcolouring of tooth crowns and roots occurred frequently. The crowns' colour is very variable from pale-creamy (almost natural) through cream-yellow to dark-grey. Roots are usually darker, in some cases even dark-brown. The extent of wear of chewing tooth surfaces was determined according to the scale proposed by H. Brabant:

0. lack of wear,
1. wear of enamel only on cusps of tooth crowns,
2. enamel worn to dentine exposed,
3. exposure of whole dentine on crown's chewing surface,
4. wear of half or more of crown's height.

Interproximal wear, involving medial and distal surfaces, in particular of molar and premolar teeth was also taken into account.¹

The problem of age evaluation on the basis of preserved dentition has been subject of discussions and surveys for many years, because in many cases it presents serious difficulties. Some authors think that precise evaluation of age is possible in the case of individuals up to 15/18 years of age. The succeeding developmental phases of deciduous and permanent teeth give a picture which is characteristic for almost each year of child's life. The age of a given person can be estimated with accuracy to ± 1 year by examination of the order of eruption of deciduous and permanent teeth, the extent of formation or resorption of deciduous tooth roots, the extent of permanent teeth formation, the width of alveoli of permanent teeth. In case of adults the basis of age estimation is the degree of dental wear, accumulation of secondary dentine leading to narrowing of pulp chamber and root canals, apposition of root cementum in the area of root's top, atrophic changes in periodontium, so-called root diaphaneity (waxiness, translucence) and tooth colour.

Root diaphaneity, which becomes visible at the age of about 25 in the apical area and progresses upwards was not observed in the examined material, probably because of long contact with the soil and multiple damage of roots. The tooth colour, bright in the beginning, growing grey or dark with time, cannot always be reliable indicator for age estimation, due to considerable dependence on the environment, e.g. on type of soil, humidity, etc.

In our material, the age of individuals under 15 years old was estimated with use of schematic diagram of Ubelaker, and for adults – according to Miles.

Difficulties also occur when one tries to determine the number of individuals buried in a grave. In the present study, a general principle was accepted that the number of individuals cannot be higher than the number of monomial teeth. However in cases when two monomial teeth (e.g. first inferior molars) clearly differ in size, morphological structure and colour, the possibility that the number of buried people was greater has been taken into account.

Odontometrical examination included measurements of mesiodistal and buccolingual diameters. Measurements of tooth germs, teeth with an advanced wear of chewing surfaces (the 3rd or 4th in the Brabant's scale), with visible wear of interproximal surfaces and teeth with damaged crowns were not taken. In few cases, we abstained from taking measurements of teeth which were fixed in alveolar bone and heavily covered with soil due to high probability of ir-

¹ Brabant's scale was chosen by Dr. Krystyna Szlachetko when research on Nemrik teeth was done in the early 1990s. It is not common in modern dental anthropology, where more detailed scales proposed by Murphy (1959) and Scott (1979) are most frequently used. Because it is not easy to recalculate precisely Brabant's scores to more detailed scales, we decided to keep them [MZ].

reversible damage of the material. Measurements were taken with use of the Martin's technique. We employed Seitz and Haag's sliding calipers (German-made Zurcher Modell) with 0.1 mm accuracy.

NK/1888

In the grave NK/1888 we found 14 permanent teeth, 3 germs of permanent teeth and minute fragments of tooth roots.

The preserved right side superior teeth are: the first and second premolars, the first and second molars and the germ of the third molar. On the left side: the first premolar, the first and second premolars and the germ of the third molar. The inferior teeth on the right side: the first and second premolars, the first and second molar teeth and the germ of the third molar are present. On the left side: the central incisor, the first and second molars. The first molars demonstrate approximately the 1st degree of crown wear. Germs of the three third molars are at the stage of crown formation. Their roots are about 1 mm long. A small fragment of a mandible remained among roots of first inferior molar tooth on the left side. The first right superior premolar has accreted roots with strongly marked groove on its medial and distal surfaces. The first superior left premolar has roots accreted along 2/3 of length and separated along 1/3 of length from the top side. Perturbations of mineralization in the form of linear hypoplasia of enamel around crowns occur. It signifies the presence of harmful factors between the age of 3 and 4 years.

On the first superior molar a tiny Carabelli's cusp is present on its left side. Three germs of third molars have fragmentary character, which is expressed in reduction of crowns' size. This individual died at age of 12–14 years.

NK/1890

In the grave NK/1890, 30 well preserved permanent teeth were found. Most of them were fixed in alveolar fragments. The root of the superior right central incisor was also found. The superior central left incisor is missing. The extent of wear was between the 1st and 2nd degree depending on tooth group, indicating the age of 18–19 years.

NK/1891

In the grave NK/1891, 17 permanent teeth, 2 roots of permanent teeth, and many small fragments of mandible were present.

The following right superior teeth are preserved: the central incisor, the canine, the first premolar and the third molar. On the left side: the lateral incisor, the canine and the third molar. Right inferior teeth: the central incisor, the lateral incisor, the first and second premolars and the first molar. The inferior left teeth included the central incisor, the canine, the second premolar, the first and second molars with slightly damaged crown. All the mentioned teeth give evidence of very advanced (4th degree) crown wear – to the pulp chambers themselves or to the cemento-enamel junction.

The degree of dental wear points to the age of about 48–50 years. Tooth measurements were not taken because of advanced wear.

NK/1948

In the grave NK/1948, 5 permanent teeth and a fragment of mandible were found.

The right half of the mandible has teeth preserved *in situ*: the first and the second premolars and the first and the second molars. Moreover alveoli of the canine and the central incisor and lateral one (lost post mortem) were present. The fifth well preserved tooth is the first right superior molar. The mentioned teeth showed the 3rd degree of wear, indicating the age of 30–36 years. Tooth measurements were not taken because of wear of a considerable part of tooth crowns.

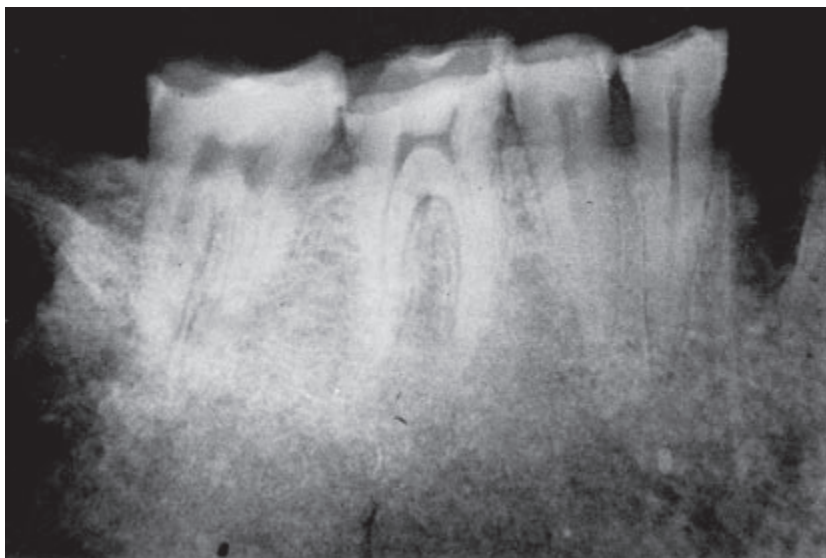


Fig. 1. NK/1948. Radiogram of the right side of the mandible with teeth preserved *in situ*.

NK/2006

In the grave NK/2006 we found 9 permanent teeth and 2 roots of permanent teeth fixed in fragments of maxilla and mandible.

In the first fragment of mandible's body are preserved *in situ* on the left side: the canine, the first and second premolars, the first and second molars with 2nd degree of dental wear. In the second fragment of mandible the presence of roots of the first and of the second premolars and the first and second molars with 2nd degree of crown wear was found *in situ*. Both fragments of mandible were held together with soil. In a small fragment of maxilla, the first and the second molars on the left side (3rd degree of crown abrasion) were preserved.

On the basis of the number of preserved teeth and of the extent of wear of their crowns the presence of two individuals at the age of 30–36 years was determined. Tooth measurements were not taken because they were stuck in fragments of heavily soiled bones.

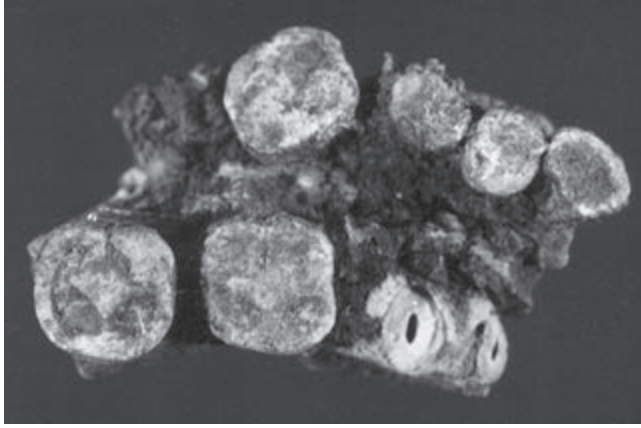


Fig. 2. NK/2006. Two fragments of the mandible with teeth *in situ*, stuck with soil.

NK/2099

In the grave NK/2099 one permanent tooth was found. This is the second right superior premolar with 4th degree of crown wear. It belongs to an individual between 45 and 50 years old. Tooth measurements were not taken because of large extent of dental wear.

NK/2133

In the grave NK/2133, 2 permanent teeth and 1 root (probably of inferior molar) were found.

They are: the superior left central incisor and the inferior left second premolar. It shows 3rd degree of crown wear. Both teeth belonged probably to the same individual aged 40–45 years. Tooth measurements were not taken because of large extent of crown wear.

NK/2329

In the grave NK/2399, there were 9 permanent teeth, 3 roots of permanent teeth and a mandible stuck together in three fragments.

In the mandible the following teeth are preserved *in situ*: on the right side the first and the second premolars and the first molar; on the left side the canine, the first and second premolars and the first, second and third molars, alveoli with broken roots of the second right molar, and left central and lateral incisors. Also alveoli of the right canine, the right central incisor and a part of the lateral one, all lost *post mortem* are preserved. The first

and the second molars show the 3rd degree, and the third molar the 2nd degree of dental wear.

On the basis of the preserved dentition, presence of a single person aged 30–36 years was determined. Tooth measurements were not taken due to the crowns' wear and positioning of teeth near the mandible (their extraction could cause irreversible damage).

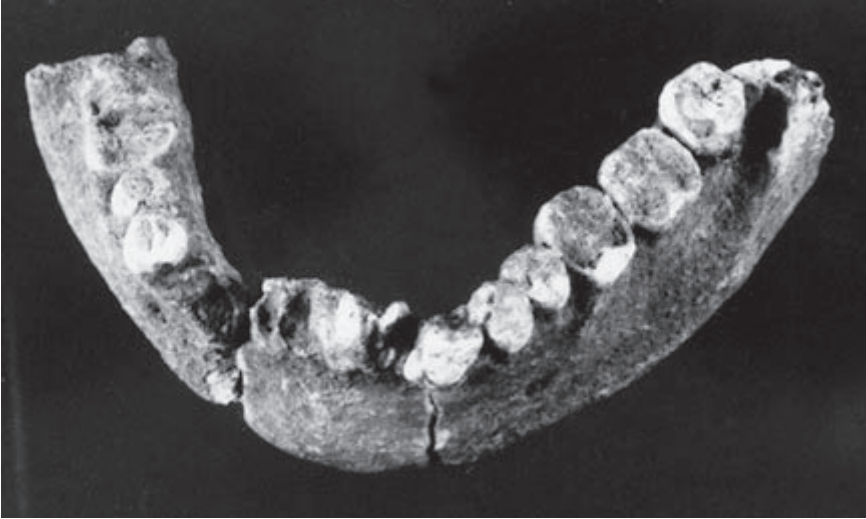

Fig. 3. NK/2329. A mandible without condylar and coronoid processes (joined three fragments).

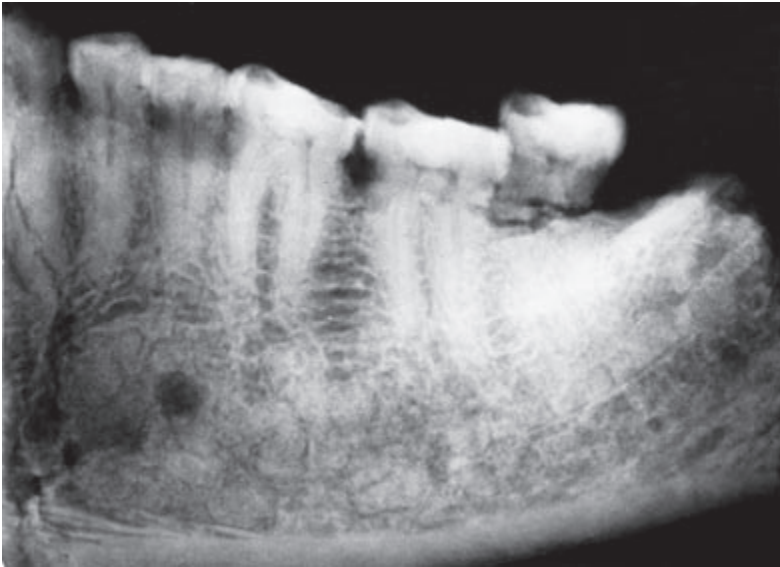


Fig. 4. NK/2329. Radiogram of the left side of the mandible presented in the previous figure.

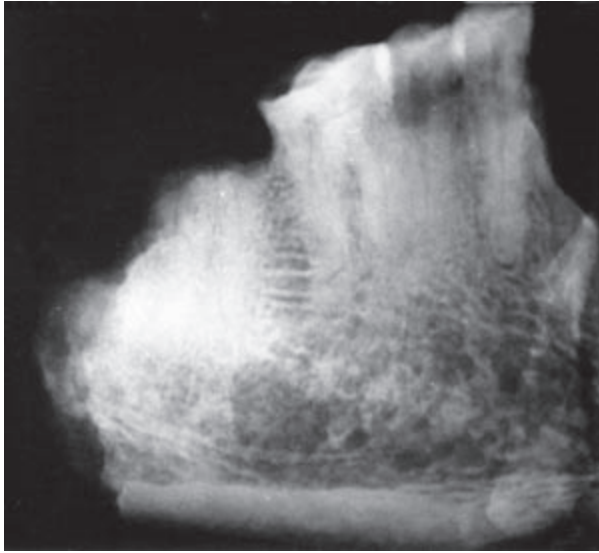


Fig. 5. NK/2329. Radiogram of the right side of the mandible presented in the **Figure 3**.

NK/2331

In the grave NK/2331, we found 21 permanent teeth, 3 roots of permanent teeth, two fragments of mandible and four fragments of maxilla and small fragments of crowns and teeth. A fragment of the central and the left part of the mandible has on its right side the preserved central incisor, and on the left side: the lateral incisor, the canine, the first and the second premolars. We found the second molar *in situ* and alveoli of the central incisor and the first left molar which was lost *post mortem*. A fragment of the mandible has: the right second premolar, the first and the second molars and the third molar preserved *in situ*. Another fragment of mandible has the following left teeth preserved: the lateral incisor, the canine, the first premolar and the root of the second premolar *in situ* and a part of the alveolus of the central incisor lost *post mortem*. A fragment of the mandible on the right side has two teeth (first and second molars) preserved *in situ*. A fragment of the mandible has the first premolar and roots of the canine tooth and the second premolar on the right side preserved *in situ*, moreover a part of the lateral incisor's alveolus. A fragment of the mandible has the second molar on the left side preserved *in situ*.

The remaining teeth not fixed in bone are the following: the superior central incisor on the right side, the superior central incisor on the left side, the first premolar inferior on the right side and the inferior first molar on the left side (fitting into an appropriate alveolus in the mandible). One tooth was not identified because of a damaged and worn crown.

Crowns of all preserved molars and premolars demonstrate the 4th degree of wear, except the third inferior molar on the right side with 2nd degree of wear. On the basis of the preserved dentition, the presence of an individual aged

about 45–50 years was determined. Tooth measurements were not taken due to considerable extent of crown wear and damage.




Fig. 6. NK/2331. Fragment of the right side of the mandible.

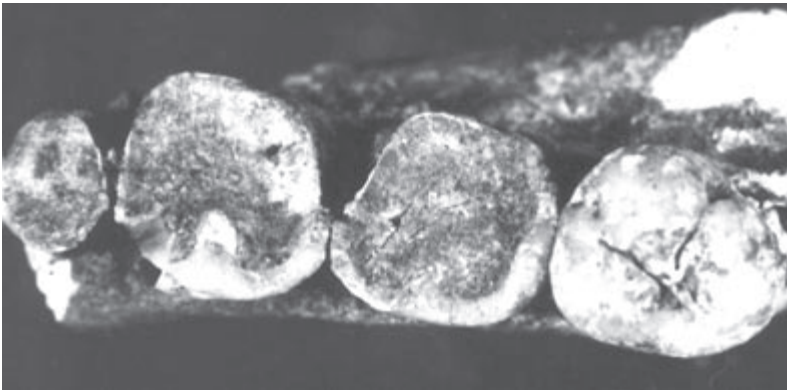


Fig. 7. NK/2331. Fragment of the mandible on the right side. The 4th degree of crown wear of the second premolar and the first and second molars, and the 2nd degree of wear of the third molar tooth crown are visible.

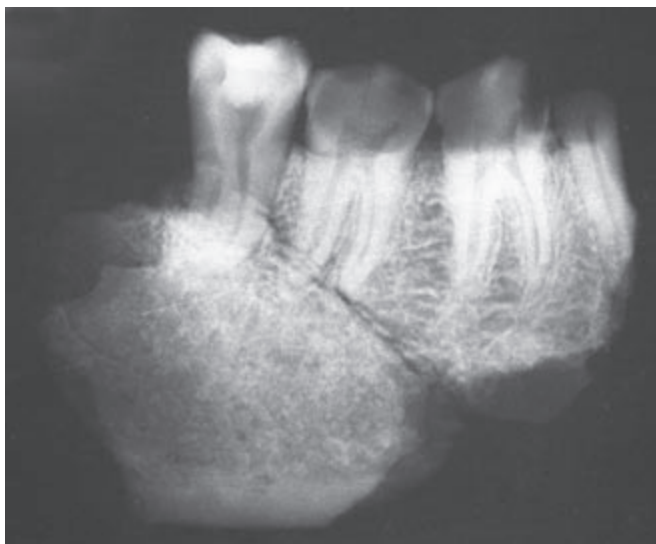

Fig. 8. NK/2331. Radiogram of a fragment of the mandible's right part presented in two previous figures.

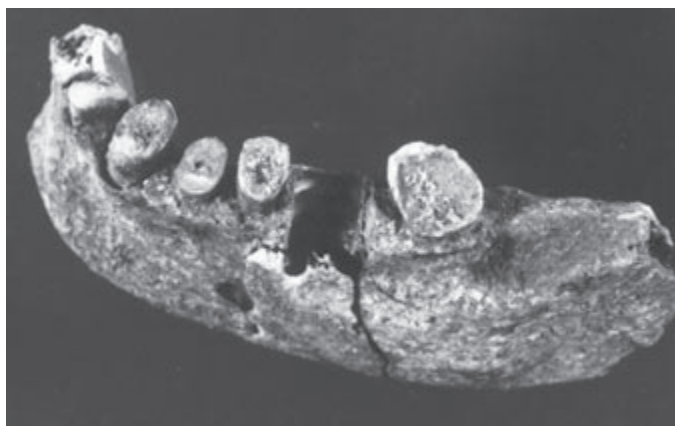


Fig. 9. NK/2331. Fragment of the central and left part of the mandible without condylar and coronoid processes.

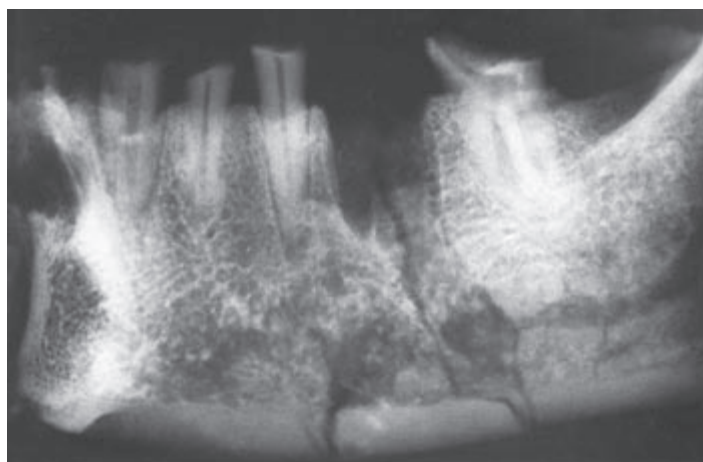


Fig. 10. NK/2331. Radiogram of the median and left part of the mandible presented in **Figure 9**. Agensy of the third molar tooth is visible.

NK/2335

In the grave NK/2335, 19 permanent teeth, 2 roots of permanent teeth, two fragments of mandible and four small fragments of maxilla were found.

In the first fragment of the mandible on the right side the lateral incisor, the canine, the first premolar, the root of the second premolar, the first, second and third molars are preserved *in situ*. In the second fragment of the mandible on the left side the root of the second premolar, the first, second and third molars are preserved *in situ*.

In the maxilla on the left side the first and second premolars are preserved *in situ*. Similarly the superior right canine, the superior right first molar and the superior left second molar were fixed in small fragments of the maxilla.

The remaining preserved teeth are: the superior right first premolar, the superior right second molar, the superior left first molar, the inferior right central incisor and the inferior left first premolar.

Crowns of the first and second molars demonstrate the 2nd degree of wear, and the third molar – the 1st degree of wear.

On the basis of the number of preserved teeth and extent of their crowns' wear, the presence of an individual aged approximately 30–36 was determined. Measurements of the remaining permanent teeth were not taken – they are fixed in bones and show advanced extent of wear of crowns.

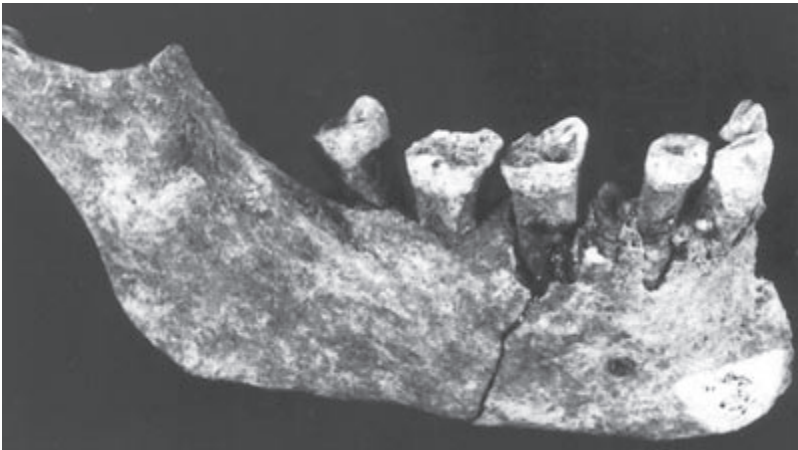


Fig. 11. NK/2335. Fragment of mandible (the central part and the right side).

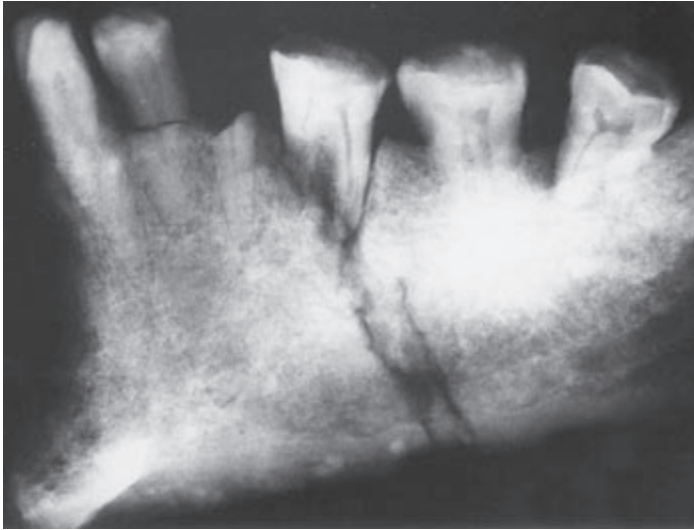


Fig. 12. NK/2335. Radiogram of mandible from **Figure 11**.

NK/2336

In the grave NK/2336, 11 permanent teeth, 1 root of a permanent tooth and three fragments of mandible were found.

The fragment of the mandible on the left side has second and third molars preserved *in situ* and a part of the alveolus of the first molar, lost *post mortem*. The fragment of the central part and partial mandible's left side has the first and second premolars preserved, the canine and the root of the lateral incisor *in situ* and moreover partial alveoli of both central incisors. The fragment of the mandible on the right side has the second molar preserved *in situ* and a part of an alveolus of the first molar lost *post mortem*.

Apart from above-mentioned teeth, the following are preserved: the superior second molar on the right side, the inferior first molar on the left side, the inferior second premolar on the right side, the lateral incisor on the right side and the central incisor on the right side. The molars demonstrate the 2nd degree of wear.

On the basis of the preserved dentition, we determined the presence of an individual about 18–24 years old.

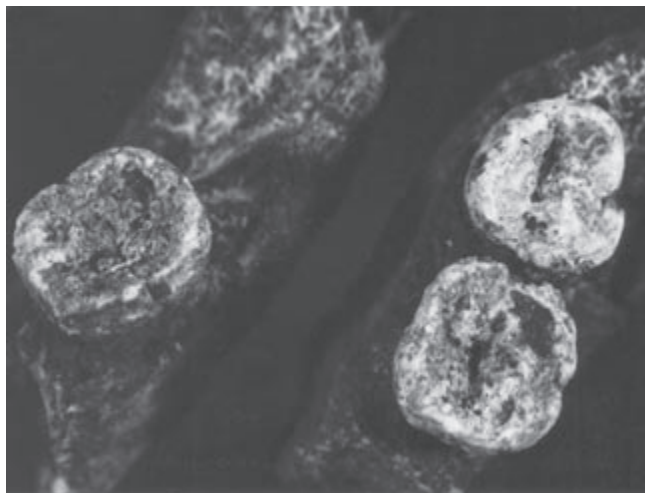


Fig. 13. NK/2336. Fragments of the mandible on the right side with preserved second molar in situ and a fragment of the mandible on the left side with preserved second and third molars *in situ*.

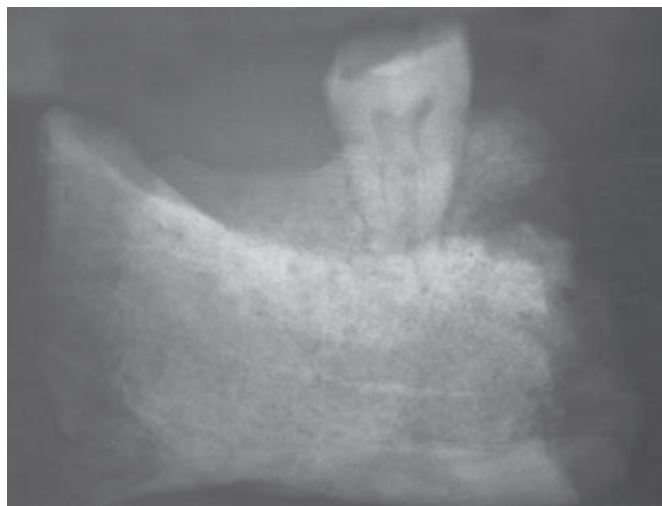

Fig. 14. NK/2336. Radiogram of the mandible's right part. Agenesis of the third molar is visible.

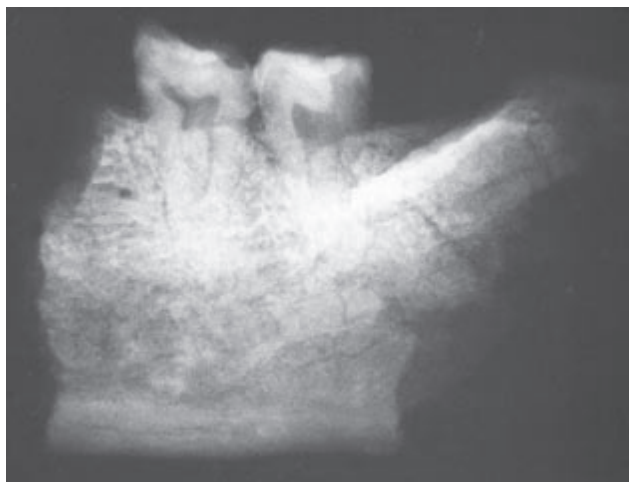

Fig. 15. NK/2336. Radiogram of the mandible's left part. The second and third molars are visible.

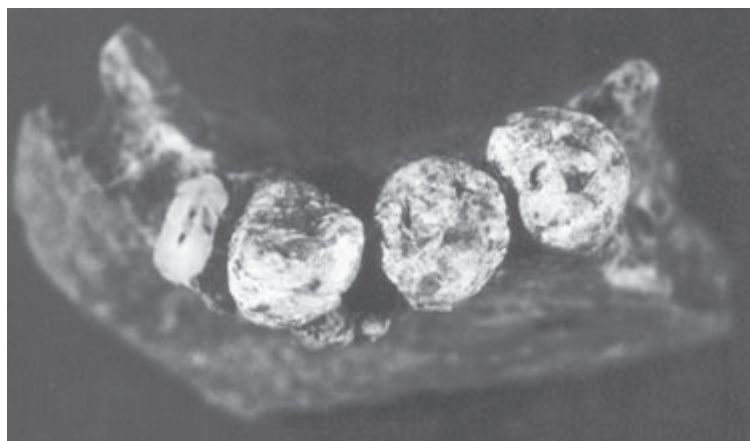


Fig. 16. NK/2336. Fragment of the central part and the mandible's left side with preserved teeth.

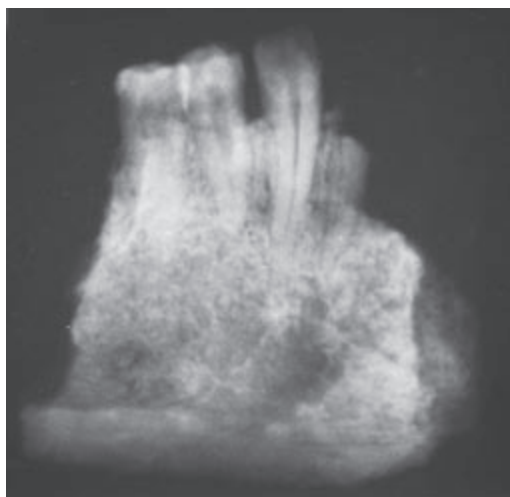


Fig. 17. NK/2336. Radiogram of the central part and the mandible's left side presented in the previous figure.

NK/ 2337

In the grave 2337, 8 permanent teeth, 3 roots of permanent teeth and three fragments of mandible were found.

The fragment of the mandible on the right side has the first and second premolars *in situ* and alveoli of central and lateral incisors and the canine preserved, all lost *post mortem*. The fragment of the mandible on the left side has the first and second molars and the root of the second premolar preserved *in situ* and the alveolus of the third molar lost *post mortem*. The fragment of the mandible on the left side has the following teeth preserved: the first and second premolars and a part of the first molar preserved *in situ*, and moreover the alveolus of the canine and a part of the alveolus of the lateral incisors lost *post mortem*. In the area of the canine's apex, a perforation of the alveolar process is visible on the external (vestibular) surface. It can result from chronic bone inflammation, e.g. granuloma.

Apart from the above-mentioned teeth, the superior central incisor on the left side, the second superior left molar and the distal root of the inferior left molar are preserved. The crowns of permanent teeth demonstrate the 4th degree of wear.

On the basis of the preserved dentition, the presence of two individuals aged 45–50 years was determined. Tooth measurements were not taken because of considerable crown wear.

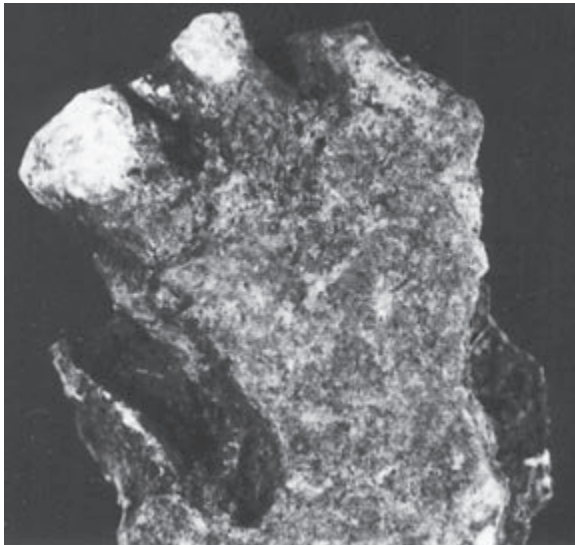


Fig. 18. NK/2337. Fragment of the mandible on the left side with premolars preserved *in situ*.

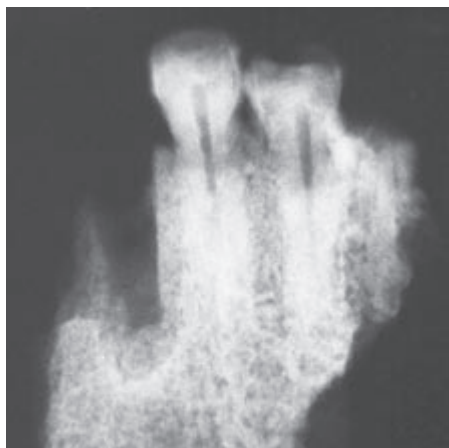


Fig. 19. NK/2337. Radiogram of a fragment of the mandible on the left side presented in the previous figure. Granuloma at canine's apex is visible.

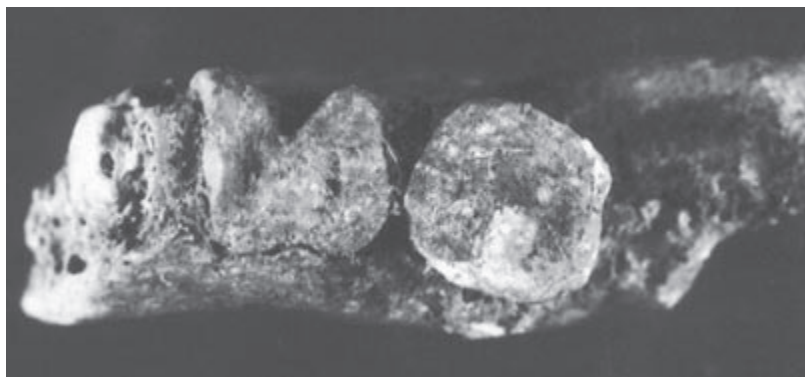


Fig. 20. NK/2337. Fragment of the mandible on the left side with the first and second molars and the root of the second premolar preserved *in situ*.

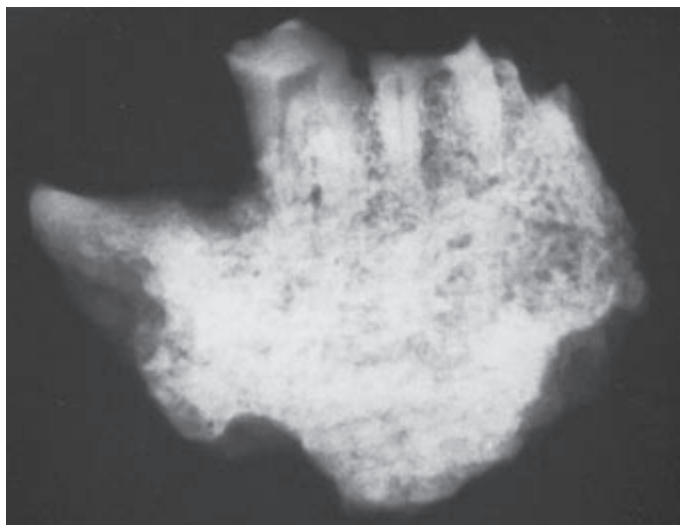


Fig. 21. NK/2337. Radiogram of a fragment of the mandible on the left side presented in the previous figure.

NK/2393

In the grave NK/2393, 33 permanent teeth, 6 fragments of crowns and tooth roots, two small fragments of bone were found.

The preserved superior teeth on the right side are the following: the lateral incisor, the canine, the first and second premolars and the first, second and third molars. On the left side: the central incisor, the lateral incisor, the canine, the first and second premolars, the first two molars, the second and third molars. Of the inferior teeth the following are preserved on the right side: the central incisor, the lateral incisor, the canine, the first and second premolars, the first molar and two second molars. On the left side: the lateral incisor, the canine, the first premolar, two second premolars, the first molar, two second molars and the third molar.

The crowns of first molars demonstrate the 2nd degree of wear, and the crowns of second molars – the 1st degree of wear. On the basis of the preserved dentition, the presence of two individuals about 18–22 years old was determined.

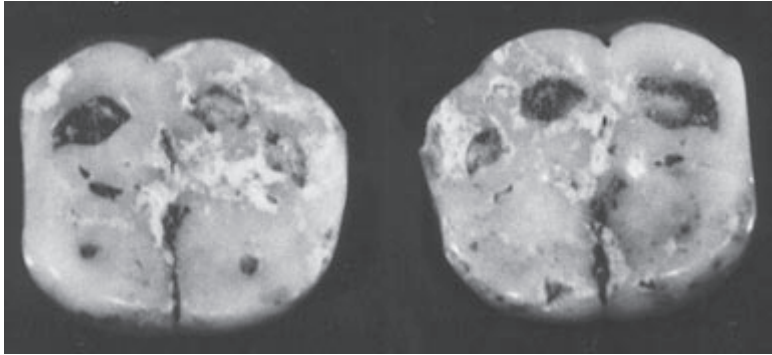


Fig. 22. NK/2393. Six-cusp crowns of first inferior molars with the 2nd degree of wear.

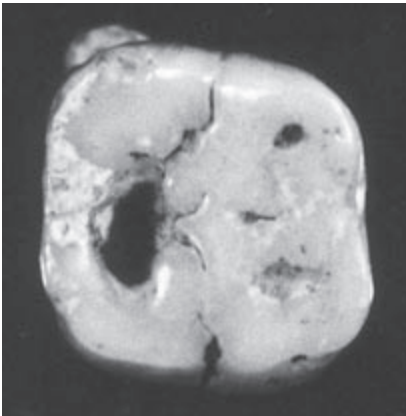


Fig. 23. NK/2393. Cariotic defect on the chewing surface of the first superior left molar. The tooth probably had three-root structure, but with four canals.

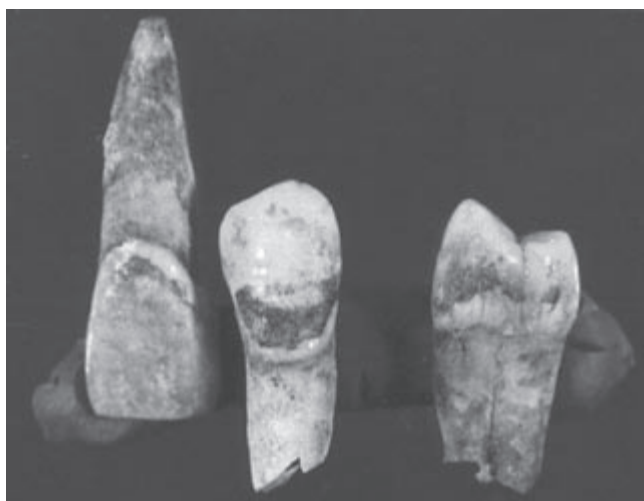

Fig. 24. NK/2393. The superior central incisor, the superior first premolar and the inferior canine with traces of calculus.

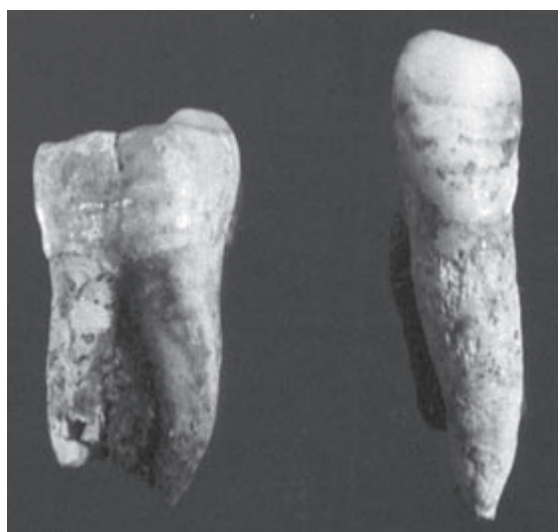

Fig. 25. NK/2393. The superior second molar and the inferior canine. Linear hypoplasia of enamel is visible.

NK/2394

In the grave NK/2394 we found one tooth – the inferior second premolar on the left side, with the 3rd degree of crown wear. It indicates the presence of an individual aged 25–30. Tooth measurements were not taken because of crown wear.

NK/2395

In the grave NK/2395, the presence of 23 permanent teeth and few single fragments of crowns and tooth roots was discovered.

The following teeth are preserved: in the maxilla the first and second molars, the first premolar on the right side and the canine on the left side; in the mandible the first and second molars and the first premolar on the right side and the second premolar and the second molar on the left side. The molars show the 1st degree of wear, the premolars are not worn. Apart from this, a germ of the third inferior molar on the right side was found. All the mentioned teeth belonged probably to a single individual aged 11–12.

The remaining teeth are: in the maxilla on the right side the third molar, the first premolar and the canine, and on the left side the lateral incisor and the first molar; in the mandible on the right side the lateral incisor and the first and second molars, on the left side the first and second premolars, and the first, second and third molars. Those teeth demonstrate considerable wear in comparison with the previously described ones (the first molars demonstrate the 4th degree of wear). On this basis, the age of the second individual was determined at 45–50 years.

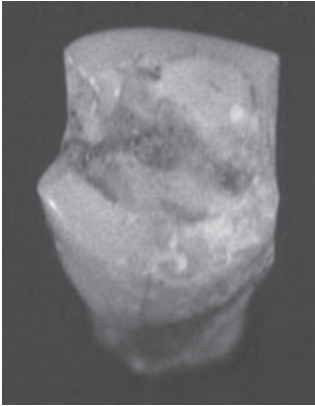


Fig. 26. NK/2395. The first inferior premolar on the left side. Considerable wear of interproximal surfaces is visible.

NK/2408

In the grave NK/2408, a fragment of a mandible on the right side with the second molar *in situ* and alveoli of the first molar and partly the second premolar lost *post mortem* were found. The extent of wear of the preserved tooth was stated as 2. It belonged to one individual aged 36–38. Tooth measurements were not taken due to considerable extent of crown wear.




Fig. 27. NK/2408. Fragment of mandible on the right side with the second molar *in situ*.

NK/2423

In the grave NK/2423, 19 permanent teeth and one deciduous tooth were found.

The following permanent superior teeth are preserved on the right side: the lateral incisor, the canine, the first and second premolars and the first, second and third molars, and on the left side: the canine, the first and second premolars and the first, second and third molars. Of the inferior teeth on the right side: the first and second premolars; on the left side: the lateral incisor, the canine, and the first and second molars. The preserved permanent teeth show the 2nd degree of wear. The first inferior molar is a three-root one, and the superior third molar has enamel pearl.

As far as deciduous teeth, the second inferior molar on the right side was found. The degree of resorption was impossible to estimate because of root damage. On the basis of the preserved dentition, the presence of two individuals aged 9–10 and 20–26 was determined.

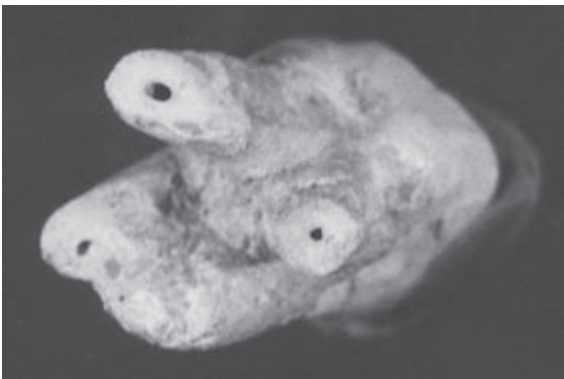

Fig. 28. NK/2423. Inferior first molar of three-root structure with four canals.

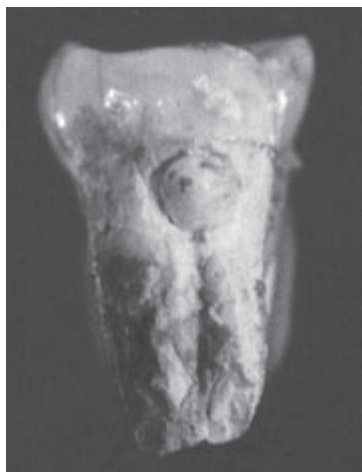

Fig. 29. NK/2423. The third superior right molar with enamel pearl on the lingual root surface, near the anatomical neck.

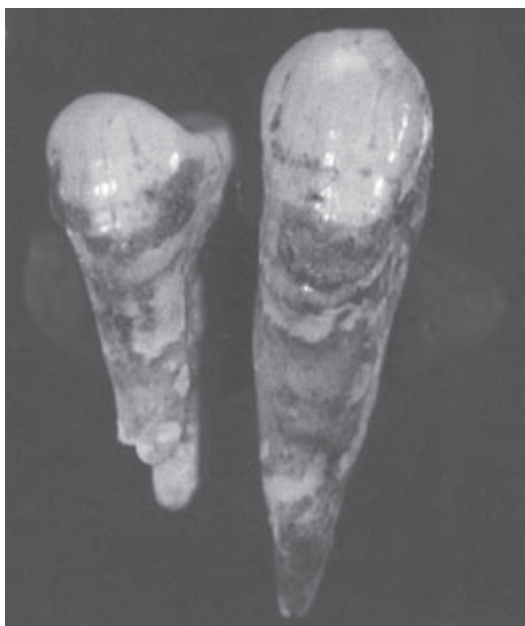

Fig. 30. NK/2423. The inferior left canine and the inferior first right premolar with signs of calculus.

NK/2437

In the grave NK/2437, 15 permanent teeth, among them 1 tooth germ were found.

The following teeth in the maxilla on the right side are preserved: the central and lateral incisors, the first and second premolars and the germ of the third molar, and on the left side: the lateral incisor and the second premolar. The following teeth in the mandible on the right side are preserved: the central and lateral incisors, the first and second premolars and the first molar, and on the left side: the central incisor, the canine and the first molar.

Four of the mentioned teeth demonstrated the 4th degree of wear. They were the following ones: the central inferior incisor on the left side, the second inferior premolar on the right side and both inferior first molars. The degree of wear of the remaining teeth was determined as 1.

On the basis of the preserved dentition, the presence of two individuals – a child aged 11–12 years and an adult of 45–50 years was determined.

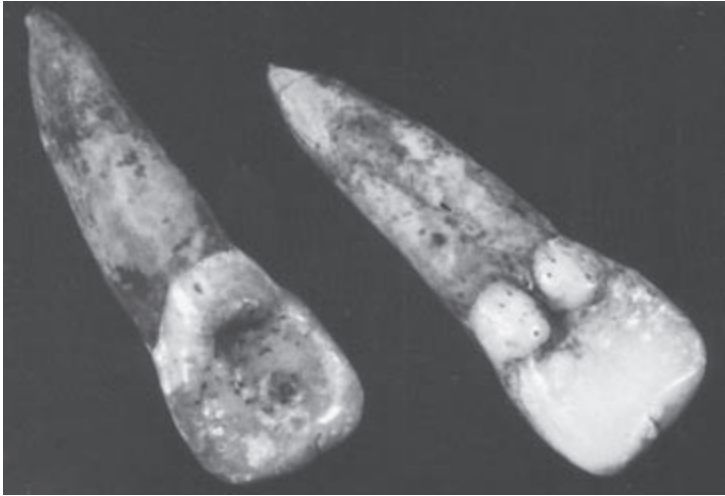

Fig. 31. NK/2437. Different forms of lingual surfaces of superior lateral incisor.

NK/2445

In the grave NK/2445 23 permanent teeth and a minute fragment of a bone was found.

The following superior teeth on the right side are preserved: the central incisor, the first and second premolars, the first and second molars. On the left side: the central incisor, the canine, the first and second premolars, the first and second molars. The inferior teeth on the right side: the canine, the second premolar, the first and second molars and probably the third molar. On the left side: the central and lateral incisors, the canine, the first and second premolars, the first and second molars. The central superior left incisor has a damaged crown.

The crowns of the first molars demonstrate the 2nd degree of wear, and the crowns of the remaining ones the 1st degree of wear. The presence of an individual aged about 16–20 years was determined on the basis of the number of preserved teeth and the extent of their crowns' wear.

NK/2511

In the grave 2511, 23 permanent teeth and a fragment of a mandible were found.

The fragment of the mandible on the right side has alveoli of the first and second premolars preserved and partly of the canine, lost *post mortem* and moreover a part of the first molar's alveolus with a broken central root of the tooth *in situ*, visible only in a radiological photograph.

The preserved superior teeth on the right side are: the lateral incisor, the first and second premolars and the first, second and third molars. On the left side: the first and third molars with a Carabelli's cusp. The preserved inferior teeth on the right side are: the central and lateral incisors, the canine, the first and second premolars, the first second, and third molars. On the left side: the

central and lateral incisors, the first and second premolars and the first, second and third molars. The crowns of the first molar teeth demonstrate the 1st degree of wear, the crowns of second molars are not worn. The third molars have 1/3 length of roots formed.

On the basis of the preserved dentition, the presence of an individual aged about 14–15 years was determined.

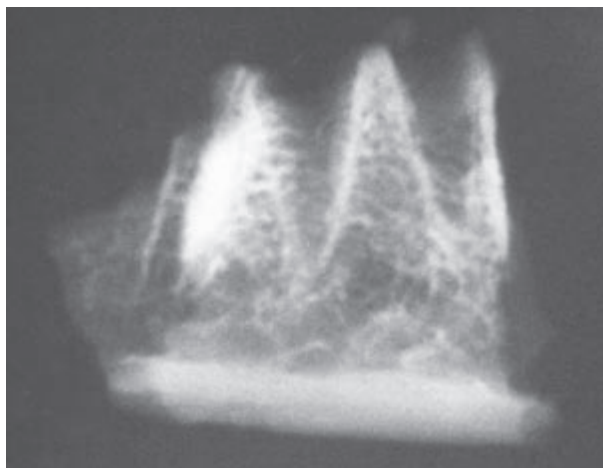


Fig. 32. NK/2511. A fragment of the mandible on the right side. Alveoli of teeth lost post mortem are visible, one with part of the root.

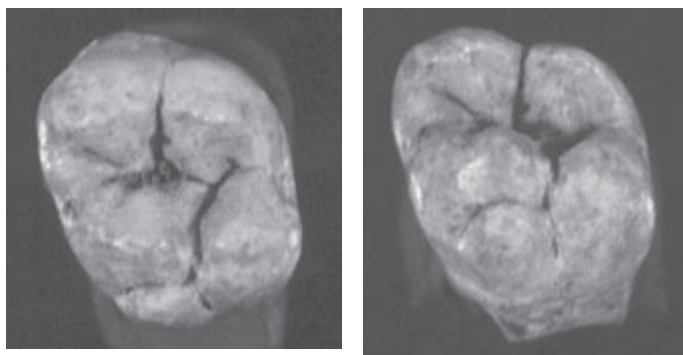


Fig. 33 a, b. NK/2511. Carabelli's cusp in the superior third molar.

NK/2512

In the grave NK/2512, 5 well preserved permanent teeth and a fragment of a root were found.

The first inferior premolar on the left side, the superior first premolar and the second molar on the right side, the second and third molars on the left side are preserved. The crowns of the first premolars demonstrate the 2nd de-

gree of wear and the crowns of the second molars and the third molar – the 1st degree of wear.

On the basis of the number of preserved teeth and the degree of their crowns' wear, the presence of an individual aged 20–25 years was determined.

NK/2356

In the grave NK/2356 19 permanent teeth were found.

The preserved superior teeth on the right side are: the canine tooth, the first and second premolars and the second and third molars. On the left side: the central incisor, the first and second premolars and the first, second and third molars. Of the inferior teeth on the right side: the canine, the second premolar and the first and second molars are preserved. On the left side: the first and second premolars and the first and second molars. The crowns of the first molars demonstrate the 4th degree of wear, the crowns of the second molars – the 3rd degree of wear, and the crown of the third superior molar on the right side demonstrates the 2nd degree of wear.

On the basis of the preserved dentition, the presence of an individual about 36–40 years old was determined. Tooth measurements were not taken because of considerable extent of wear of chewing and interproximal surfaces of the crowns.

NK/2547

In the grave NK/2547, one permanent tooth was found. It is the superior lateral incisor on the right side with traces of calculus and the 1st degree of crown wear. It belonged to an individual about 20 years old.

NK/2549

In the grave NK/2549, one permanent tooth was found: the superior third molar on the left side with the 1st degree of crown wear. It belonged to an individual 22–25 years old.

NK/2623

In the grave NK/2623, two permanent teeth are preserved. They are: the superior second molar on the left side and the inferior first molar on the right side. They demonstrate the 2nd degree of crown wear. On this basis the presence of one individual aged 30–34 was determined.

Tooth measurements were not taken because of the wear of a considerable part of crowns.

NK/2627

In the grave NK/2627 one permanent tooth was found: the superior canine on the right side with the 2nd degree of wear. It belonged to an individual 25–30 years old.

NK/2628

In the grave NK/2628 4 permanent teeth were found. They are: the superior second molar on the left side, the first, second and third inferior molars, also on the left side. They demonstrate the 4th degree of wear.

They belonged to an individual aged 44–48 years. Because of a considerable extent of crown wear, tooth measurements were not taken.

NK/2634

In the grave NK 2634 2 permanent teeth and 2 deciduous teeth were found. The preserved permanent teeth are: the superior second molar on the left side and the inferior canine on the right side. They indicate the 1st degree of wear.

The preserved deciduous teeth are the first and second inferior molars on the right side. They have formed roots, without traces of resorption, and the degree of their wear was evaluated as 1.

On the basis of the preserved dentition, the presence of two individuals: a child aged about five years and an adult 18–20 years old was determined.

NK/2638

In the grave NK/2638, 20 permanent teeth and small fragments of crowns and tooth roots were found.

The preserved superior teeth on the right side are: the canine, the first and second premolars and the second molar. On the left side: the central incisor, the second premolar, the first and third molars. The inferior teeth on the right side: the central incisor, the lateral incisor, the first and second premolars. On the left side: the lateral incisor, the canine, the first and second premolars, the first and second molars. The crowns of the first molars and the inferior second molars demonstrate the 2nd degree of crown wear and the crown of a second superior molar on the right side – the 1st degree of wear.

On the basis of the preserved dentition, the presence of an individual aged 26–30 years was determined.

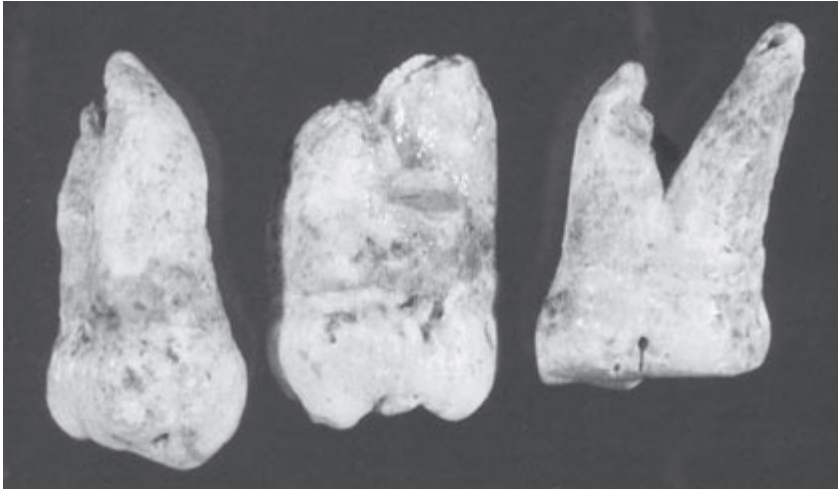


Fig. 34. NK/2638. Three molars, the middle tooth with external features of taurodontism, excluded by radiological examination.

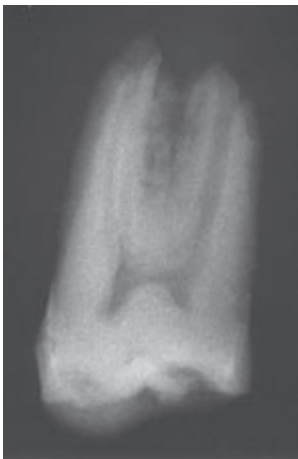

Fig. 35. NK/ 2638. Radiogram of the tooth with external features of taurodontism from **Figure 34**.

NK/2639

In the grave NK/2639, 9 permanent teeth, 10 germs of permanent teeth, 3 deciduous teeth and a small fragment of tooth's germ were found.

As far as the permanent teeth, four of them demonstrated the 1st degree of crown wear. They were: the superior first molar on the right side, the inferior first and second molars on the right side and the inferior first molar on the left side fixed in a small fragment of bone.

Two teeth, the first superior molar on the right side and the central superior incisor on the left side demonstrated the 2nd degree of crown wear.

The three remaining permanent teeth are both central incisors and the inferior lateral incisor on the left side with roots not completely formed.

Germs of the following teeth: the superior first molar on the right side, the superior first premolar on the left side, the inferior canine, the first and second

premolars and the first molar on the right side, the inferior canine, the first and second premolars and the first molar on the left side are also preserved.

The preserved deciduous teeth are: the superior canine at the left side, the inferior first molar on the right side and the inferior first molar on the left side.

On the basis of the preserved dentition, the presence of three individuals: two children 8–9 years old and 10–11 years old and an adult 30–36 years old was determined.

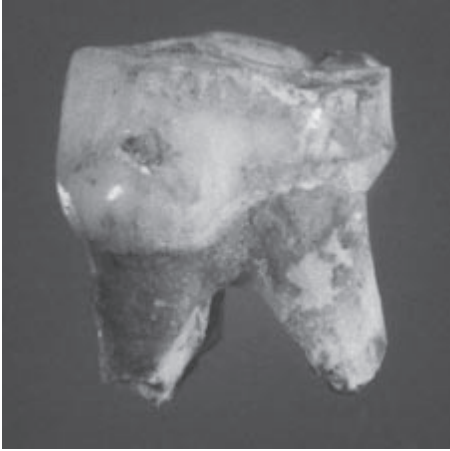


Fig. 36. NK/2639. The first inferior left deciduous molar.

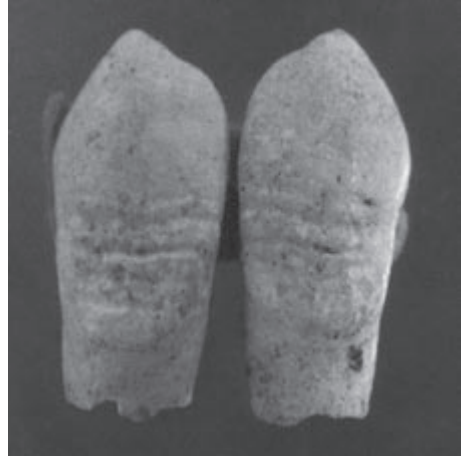

Fig. 37. NK/2639. Linear hypoplasia of enamel on crowns of inferior permanent canine germs.

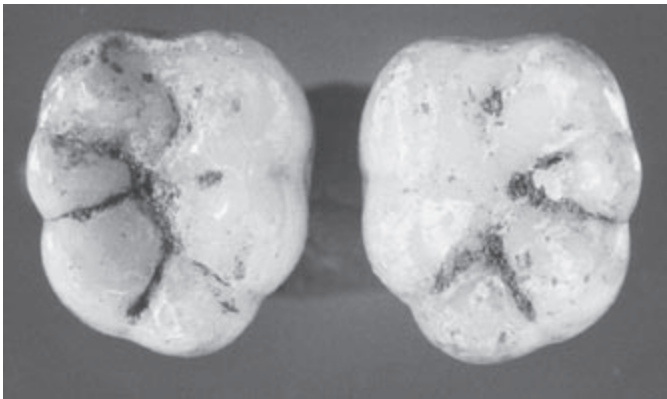


Fig. 38. NK/2639. The inferior first molars of six-cusp crowns.

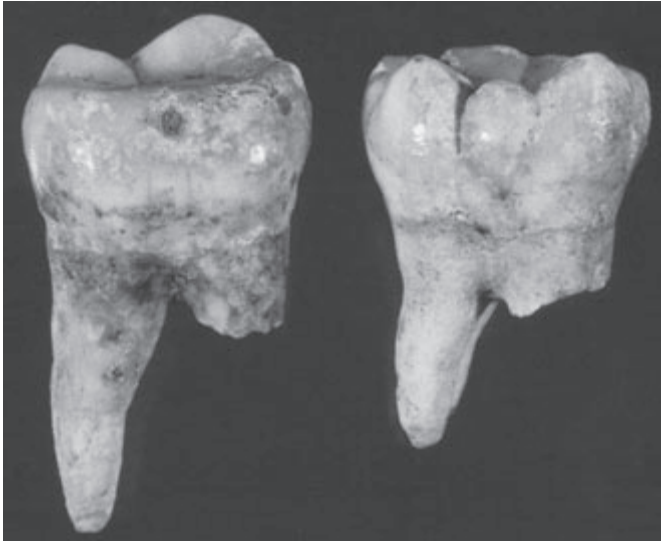


Fig. 39. NK/2639. The course of cemento-enamel junction in inferior molars.

NK/2701

In the grave NK/2701, 4 well preserved superior permanent teeth were found. They are: the right and left lateral incisors, the right canine and the right first premolar. Apart from this, a small fragment of inferior left molar's crown is preserved.

The degree of teeth wear was evaluated as 3–4. It indicates the presence of one individual aged about 40–42 years. Tooth measurements were not taken because of a considerable extent of wear.

NK/2704

In the grave NK/2704, 8 permanent teeth, small fragments of crowns and roots of incisors and premolars and small fragments of bones were found.

The preserved superior teeth are the following ones: a first premolar and a second molar on the left side. From the midst of inferior teeth on the right side: the first, second and third molars are preserved and on the left side: also the first, second and third molars.

The second superior left molar demonstrates reduction of hypoconus and shift of metaconus towards the palate and considerable extension of buccolingual dimension.

The crowns of the first molar teeth demonstrate the 2nd degree of wear and the second molars – the 1st degree of wear. The crowns of all teeth are damaged. On the basis of the preserved dentition, the presence of an individual aged about 18–20 years was determined.

NK/2709

In the grave NK/2709, 17 permanent teeth, two fragments of mandible and small fragments of bones, crowns and tooth roots were found.

Of the teeth preserved in the maxilla there are: on the right side the first premolar and the first molar, on the left side the canine, the second premolar and the first and second molars; in the mandible on the right side the central incisor, the first and second premolars, the first and second molars; on the left side the canine, the first premolar and the second molar. Three teeth are not suitable for exact identification because of extensive root damage and crown wear of the 4th degree to the cemento-enamel junction. All mentioned teeth demonstrate the 3rd-4th degree of wear.

Apart from the described teeth, a fragment of the mandible on the left side with alveoli of the first premolar and the second molar lost *post mortem* were found. The alveolar process among those alveoli is resorbed, which indicates a loss of the second premolar and the first molar *ante mortem*. The second preserved bone fragment is an external part of mandible on the right side.

On the basis of the preserved dentition, the presence of an individual 42-46 years old was determined. Tooth measurements were not taken due to the crowns' advanced wear.

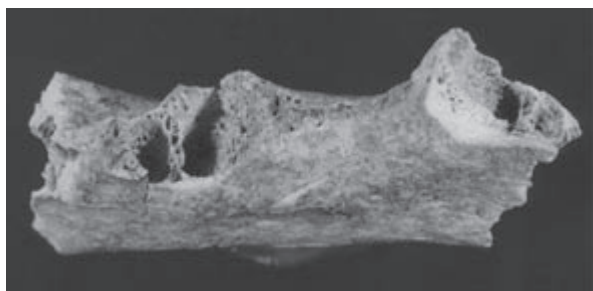
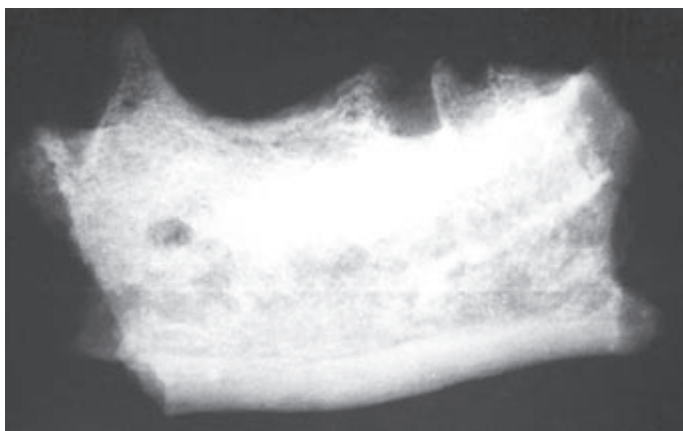


Fig. 40. NK/2709. Fragments of mandible's body on the left side with alveoli of the first premolar and the second molar, lost *ante mortem*.

Fig. 41. NK/2709. Radiogram of mandible on the left side from **Figure 40**. The resorbed alveolar process and reconstruction of bone structure at the site of the second premolar and the first molar indicate a loss of those teeth *ante mortem*.



NK/2724

In the grave NK/2724, 2 permanent teeth, few small fragments of teeth, a fragment of mandible and two small fragments – one of maxilla, the other of mandible – were found.

The first and second premolars on the right side are preserved. A fragment of the central part of the mandible has alveoli of both central incisors, the lateral left incisor and partly the left canine, all lost *post mortem*. The crowns of the two preserved teeth demonstrate the 1st degree of wear.

On the basis of the preserved teeth, the presence of an individual aged 15–18 years was determined.

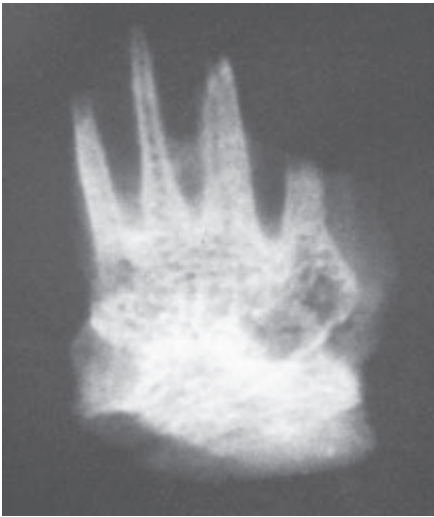

Fig. 42. NK/2724. Radiogram of a fragment of mandible's body. Alveoli of both central incisors, the lateral left incisor and the left canine are visible, all teeth lost *post mortem*.

NK/2732

In the grave NK/2732, 22 permanent teeth were found.

On the superior right side there are: the central and lateral incisors, the canine and the third molar; inferior teeth: the central and lateral incisors, the canine, the second premolar, the first and second molars. On the left superior side there are: the central incisor, the canine, the first premolar and the first, second and third molars; inferior teeth: the central incisors, the second premolar, the first, second and third molars.

The first molars demonstrate the 2nd degree and the second molars – the 1st degree of crown wear. The first left superior premolar has the 3rd degree of a crown wear and a different, darker colour of the crown and the root.

On the basis of the preserved dentition, the probable presence of two individuals about 18–24 years old and 35–40 years old was determined.

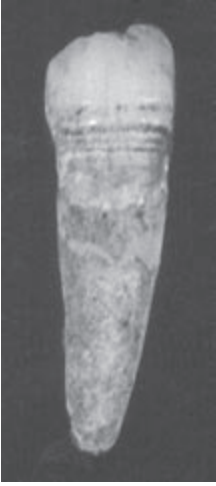

Fig. 43. NK/2732. The inferior right side of permanent canine tooth. Linear hypoplasia of enamel is visible.

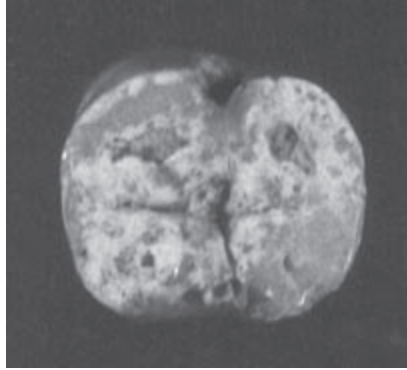


Fig. 44. NK/2732. The inferior second permanent molar tooth on the right side. Hypoplasia of enamel is visible in the area of foramen coecum.

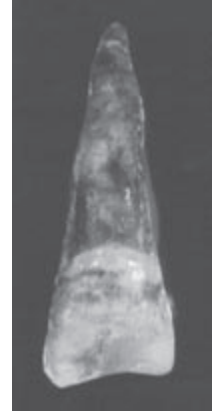

Fig. 45. NK/2732. Non-typical abrasion of incisal ridge of the superior lateral left permanent incisor.

NK/2764

In the grave NK/2764, 2 well preserved permanent teeth and few fragments of crowns and tooth roots were found.

The first inferior premolar on the left side and the second molar, also on the left side are well preserved. Among fragments of teeth, one is probably a damaged central incisor. The mentioned teeth demonstrate the 1st degree of crown wear. They belonged to one individual aged about 20 years.

NK/2768

In the grave NK/2768, 21 permanent teeth, three small fragments of tooth roots and a small fragment of mandible were found.

The central incisor, the lateral incisor, the canine, the first and second premolars and the second molar are the superior teeth preserved on the right side; the central incisor, the lateral incisor, the canine, the first and second premolars are the superior teeth preserved on the left side. From the inferior teeth on the right side there are: the central incisor, the lateral one, the second premolar, the first and second molars; on the left side: the central incisor, the canine, the second premolar, the first and third molars.

The first molars and the first and second premolars demonstrate the 4th degree, the second molars – the 3rd degree, and the third molar – the 2nd degree of crown wear.

On the basis of the preserved dentition, the presence of an individual aged about 44–48 was determined. Tooth measurements were not taken because of a considerable extent of crowns' wear and their damage.

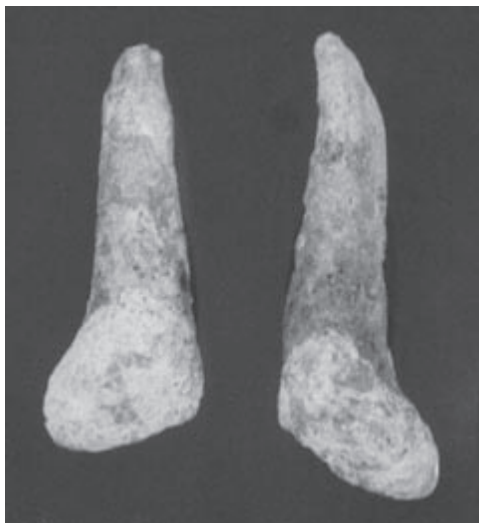

Fig. 46. NK/2768. Shape of crowns of the permanent lateral superior incisors. Labial surfaces.

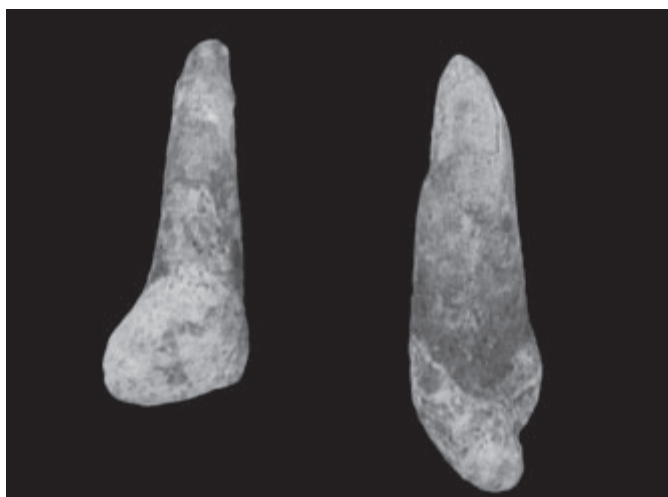


Fig. 47. NK/2768. Shape of crowns of the permanent lateral superior incisors from **Figure 46**. The right incisor from the side of labial surface, the left incisor – from the medial side.

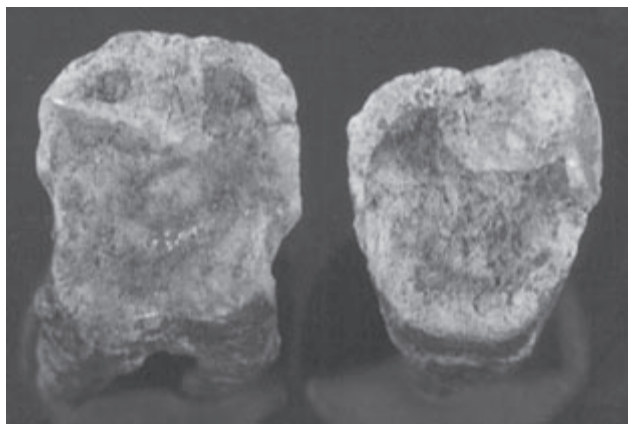


Fig. 48. NK/2768. Molars with the 4th degree of crown wear.

NK/2777

In the grave NK/2777, 2 deciduous teeth: two superior molars and germs of 3 permanent teeth, i.e. both superior first molars and the first left inferior molar were found.

Deciduous teeth do not demonstrate crown wear and have roots which are not completely formed. Only crowns of germs of permanent teeth are mineralised.

On the basis of the preserved teeth, the presence of one individual, a child about 3 years old was determined.

NK/2801

In the grave NK/2801, 13 permanent teeth and small fragments of crowns and tooth roots were found.

From the superior teeth the second central incisor, the first and third molars are preserved on the right side; the second central and the third molar – on the left side. From the inferior teeth the central incisor and the lateral one, the first and second premolars and the second molar are preserved on the right side; the first premolar, the first and third molars on the left side.

The degree of first molar's wear was evaluated as 2, the remaining teeth demonstrate the 1st degree of wear.

On the basis of the preserved teeth, the presence of one individual 24–26 years old was determined.

NK/2802

In the grave NK/2802, a well preserved skull of a child with almost complete maxilla and mandible was found.

After a partial, careful cleaning from soil, the following teeth were found in the mandible: on the right side the central incisor, the first permanent molar,

the lateral deciduous incisor, the deciduous canine, both deciduous molars. On the left side the first molar, the deciduous canine and both deciduous molars. In the maxilla the central permanent incisor on the left side and germs of permanent canines in bone niches are visible.

On the basis of the preserved dentition, the child's age was estimated at 6–7 years. Tooth measurements were not taken because of possibility of damage of the material.

NK/3341

In the grave NK/3341, 29 well preserved teeth were found, including the following superior teeth: the central incisor, the lateral incisor, the canine, the first and second premolars, the two first molars, the two second molars and the two third molars on the right side. On the left side: the central incisor, the lateral one, the first premolar, the first, second and third molars. The inferior teeth: the first and second premolars, the first second and third molars are preserved on the right side. On the left side: the canine, the first and second premolars, the first, second and third molars. The first, second and third molars on the right side and the same teeth on the left side are fixed in fragments of maxillae *in situ*.

The two first molars, the superior incisors and the canine demonstrate the highest extent of wear – the 2nd degree. The remaining teeth demonstrate the 1st degree of wear.

Apart from this, a few fragments of single roots and few fragments of roots fixed *in situ* in minute fragments of maxillae and mandibles were found.

On the basis of the number of the preserved dentition, the presence of two individuals (possibly more) 24–30 years and 20–24 years old was determined.

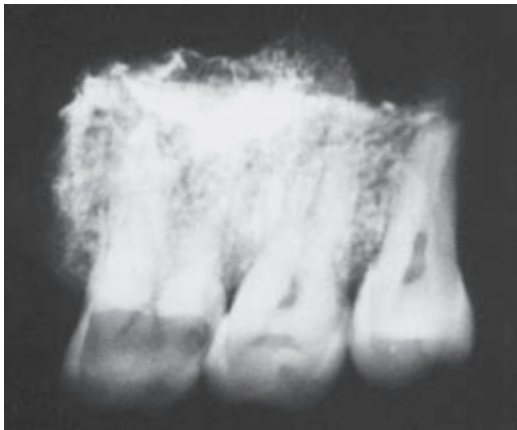


Fig. 49. NK/3341. Radiogram of a fragment of maxilla on the left side with the first, second and third molars *in situ*.

NK/3345

In the grave NK/3345, 4 permanent teeth, 1 permanent tooth's germ and 3 deciduous teeth were found.

From the deciduous teeth, both superior second molars and the first left superior molar are preserved. They demonstrate the 1st degree of crown wear.

From the permanent teeth the central superior left incisor, the first and second molars on the right side and a germ of the first superior molar on the left side were found. The incisor and the first molar demonstrate the 2nd degree of wear, the remaining teeth – the 1st degree of wear. The germ of the first superior molar on the left side has only a crown formed.

On the basis of the preserved teeth, the presence of two individuals: a child about 4 years and an adult about 20–25 years old was determined.

NK/3349

In the grave NK/3349, 3 deciduous teeth, germs of 5 permanent teeth and a root of a deciduous molar, all well preserved, were found.

From the deciduous teeth, the first inferior left molar and the inferior first and second molars on the right side fixed in the alveolar process were found. The molars demonstrate the beginning of wear in the area of cusp tops. The roots of the second inferior molar are damaged, with wide canals.

From the permanent teeth there are both germs of the inferior central incisors and three germs of the first molars: the superior one and the inferior one on the right side are characterized by a darker, identical colour, the second germ of the first inferior right molar has a pale colour, which indicates two individuals 3–4 years old.

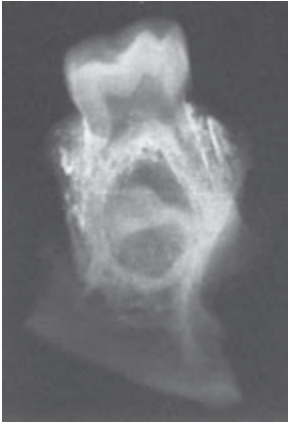

Fig. 50. NK/3349. The second inferior deciduous molar on the right side fixed in an alveolar process. On the radiogram, the germ of the second premolar at the initial phase of mineralization is visible.

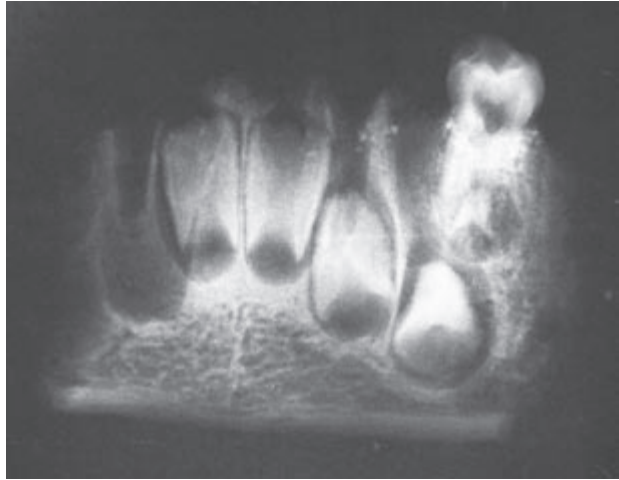


Fig. 51. NK/3349. The first inferior deciduous molar on the right side fixed in an alveolar process. On the radiogram germs of both central incisors, the right lateral incisor, the canine, the first premolar on the right side and a niche of the lateral incisor's germ on the left side are visible.

NK/3352

In the grave NK/3352, 2 deciduous teeth and 7 permanent teeth, all well preserved, and few fragments of tooth roots were found.

The deciduous teeth: the superior first left molar and the second molar are preserved. Their crowns do not demonstrate wear and their roots are usually damaged, only the medial buccal root in the second molar is not completely formed.

From the permanent teeth the following are preserved in the maxilla: on the right side the lateral incisor, the canine, the first and second premolars and the third molar tooth with crown reduced to two cusps. On the left side: the first and second molars. The first molar demonstrates the 2nd degree of wear, the second and third molars – the 1st degree of crown wear.

On the basis of the preserved dentition, the presence of two individuals, i.e. a child aged 3–4 years and an adult aged 24–30 years was determined.

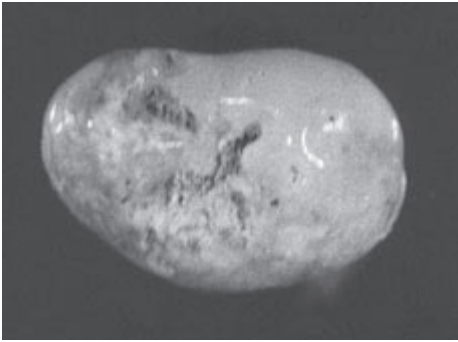


Fig. 52. NK/3352. The crown of the third superior molar on the right side, reduced to two cusps.

NK/3355

In the grave NK/3355, 4 permanent teeth and a small fragment of maxilla were found.

The preserved superior teeth are: the lateral incisor, the first, second and third molars, all on the right side. The mentioned third molar was located in the maxilla fragment *in situ*. The first molar's crown demonstrated the 2nd degree of wear, the second molar's crown – the 1st degree of wear, the third molar's crown – also the 1st degree of wear. On the basis of the preserved dentition, the presence of one individual 18–24 years old was determined.

NK/3357

In the grave NK/3357, 4 permanent teeth were found. They are: the first superior premolar on the right side, the second inferior molar on the right side and the first and third inferior molars on the left side. The first inferior molar has a damaged crown and a distal root. The crown of the second molar demon-

strates the 2nd degree of wear, the crown of the third molar – the 1st degree of wear. Evaluation of the crown wear of the first molar was impossible, due to its considerable damage.

On the basis of the number of preserved teeth and extent of their crowns' wear, the presence of one individual about 18–24 years old was determined.

NK/3361

In the grave NK/3361, 2 permanent teeth were found. They are: the superior right canine and the superior right first premolar. The crowns of the mentioned teeth demonstrate the 1st degree of wear.

On the basis of the number of preserved teeth and extent of their crowns' wear, the presence of one individual 18–20 years old was determined.

NK/3364

In the grave NK/3364, one permanent superior tooth – the canine on the left side with the 2nd degree of crown wear was found. It indicates the presence of one individual about 20–25 years old.

NK/3365

In the grave NK/3365, 2 permanent teeth and a fragment of an inferior molar's crown were found. The preserved teeth are: the first inferior premolar on the left side with crown wear of the 1st degree, and the second molar on the left side also with crown wear of the 1st degree.

On the basis of the number of preserved teeth and the degree of their crowns' wear, the presence of one individual aged about 18–20 years was determined.

NK/3372

In the grave NK/3372, 4 permanent teeth, 2 roots of permanent teeth and minute fragments of crowns and roots were found.

The preserved teeth are: the third superior molar on the right side, the first inferior molar on the left side (with a heavily damaged crown), the first inferior premolar and the third inferior molar on the right side. The crowns of the third molars demonstrate the 1st degree of wear.

On the basis of the preserved teeth, the presence of one individual aged about 24–28 years was determined.

NK/3394

In the grave NK/3394, 15 permanent teeth, one fragment of maxilla and a small fragment of mandible were found.

The fragment of the maxilla on the right side has the second premolar preserved *in situ* and alveoli of the first premolar, the canine and part of the lateral incisor, all lost *post mortem*.

The remaining preserved teeth are superior ones on the right side: the canine, the first premolar, the first and second molars. On the left side: the central incisor and the first premolar. The inferior teeth on the right side: the second premolar, the second and third molars. On the left side: the canine, the second premolar, the first, second and third molar.

The crowns of first molars demonstrate the 2nd degree of wear, and the crowns of second molars – the 1st degree of wear.

On the basis of the preserved dentition, the presence of one individual aged about 18–24 years was determined.

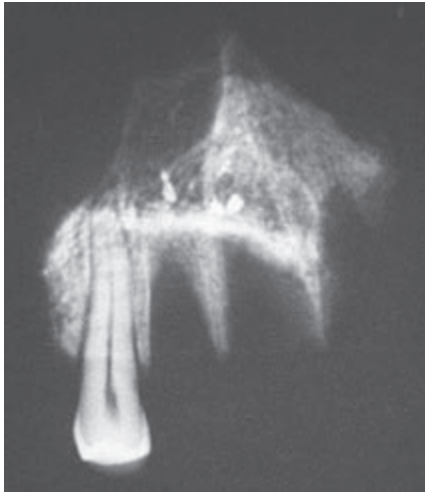

Fig. 53. NK/3394. Radiogram of a fragment of a maxilla on the right side with the second premolar *in situ* and alveoli of the first premolar, the canine and the lateral incisor, all lost *post mortem*.

NK/3396

In the grave NK/3396, 20 permanent teeth, 2 germs of permanent teeth, one deciduous tooth, one root of a permanent tooth, two fragments of mandible, a fragment of maxilla and small fragments of bones and teeth were found.

The fragment of the mandible on the right side has four teeth preserved *in situ* – the second premolar, the first, second and third molars and alveoli of the first premolar and partly the canine, all lost *post mortem*. The second fragment of the mandible is its central part and the body on the left side. It has: the lateral incisor on the right side, the canine's root, the first and second premolars and the first, second and third molars on the left side preserved *in situ*, and also alveoli of both central incisors and the lateral left incisor, all lost *post mortem*.

The remaining preserved teeth are: the inferior canine tooth on the right side, the superior central incisor on the left side, and the superior ones on the right side: the canine, the first, second premolars, the first and second molars.

All three first molars and inferior second molars demonstrate the 4th degree of wear, the second superior molar – the 3rd degree of wear and the inferior

third molars – the 2nd degree. Apart from this, the first right, deciduous molar without formed roots, and germs of the first permanent molars, the superior and the inferior one, on the right side. The first deciduous molar demonstrates a strongly formed *tuberculum morale*.

On the basis of the preserved dentition, the presence of one adult individual aged 36–42 years and a child aged about 2 years was determined.

Measurements of permanent teeth were not taken due to a considerable extent of crown wear.

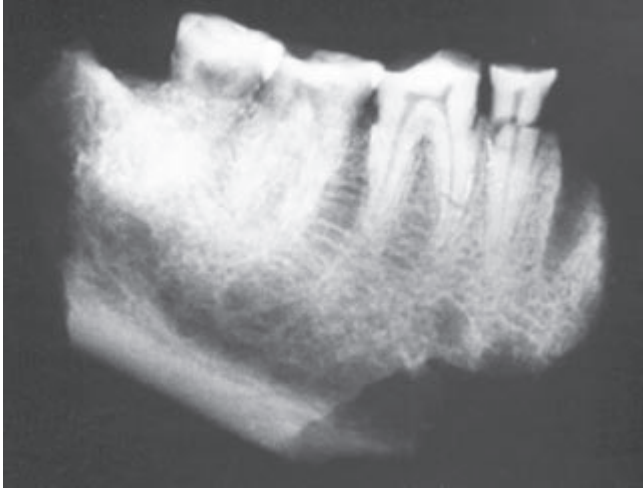

Fig. 54. NK/3396. Radiogram of a fragment of the mandible: the right side with the second premolar (damaged) and three molars *in situ*.

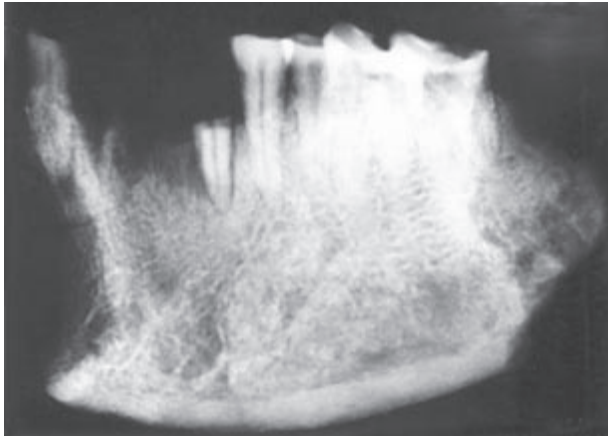


Fig. 55. NK/3396. Radiogram of the central part and mandible's body on the left side.

NK/3399

In the grave NK/3399, 7 well preserved permanent teeth were found. They are: the superior first left molar, the second molar, both inferior first and second molars and the second premolar.

The extent of wear of the first molars' crowns was evaluated as 3, the second molars and a premolar – as 2. Apart from this, three small fragments of roots and a fragment of an superior molar not fit for identification were found.

On the basis of the preserved dentition, the presence of one individual 36–40 years old was determined. Tooth measurements were not taken because of a considerable extent of crowns' wear.

NK/3400

In the grave NK/3400, 2 well preserved germs of the following teeth were found: the second deciduous molar and the first permanent molar, both superior and on the left side. On this basis, the presence of one individual, a child about 1 year old was determined.

NK/3401

In the grave NK/3401, 9 permanent teeth, two fragments of a mandible, one big and one small fragment of maxilla were found.

The fragment of the mandible on the right side has the first molar preserved *in situ* and alveoli of both premolars and partly of the second molar, all lost *post mortem*. The fragment of a mandible's front part has alveoli of both premolar incisors, partly the lateral right incisor and the lateral left incisor and the left canine, all lost *post mortem*. The fragment of maxilla on the left side has preserved alveoli of the first and second premolars and partly the first molar, all lost *post mortem*. In the damaged alveolus of the first molar, a medial buccal root with an obliterated canal is visible.

Apart from the above-mentioned first molar fixed in a fragment of a mandible, from the inferior teeth the following are preserved: the canine, the first premolar, the first, second molars on the right side and the canine with a damaged crown on the left side. From the superior teeth: the right canine and both the first molars on the left side are preserved. One of them was fitted into a medial buccal root fixed in a fragment of the maxilla. Fitting the remaining teeth into appropriate alveoli in the preserved bones was not successful.

On the basis of the number of preserved teeth, the extent of their crowns' wear and roots' colour, the presence of two individuals was determined.

One of them had the 2nd degree of crown wear of the first molars and a brighter colour of roots. His age was estimated at 15–18 years.

The other individual had the 2nd degree of wear of the first molars' crowns and a darker colour of roots. On the enamel from necks to 1/3–1/2 of heights of these teeth's crowns, linear hypoplasia of enamel was found. His age was estimated at 30–35 years.

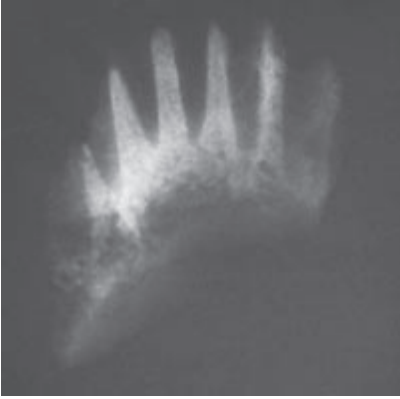


Fig. 56. NK/3401. Radiogram of a fragment of the front part of the mandible with alveoli of central and lateral incisors and canines, all lost *post mortem*.

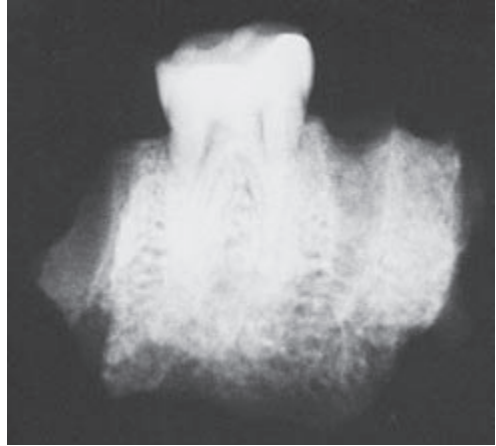

Fig. 57. NK/3401. Radiogram of a fragment of the mandible on the right side with the first molar in situ and alveoli of neighbouring teeth lost *post mortem*.

NK/3402

In the grave NK/3402, 3 permanent teeth, a permanent molar's root, a fragment of mandible and a small fragment of a bone were found.

The fragment of the mandible on the left side has an inferior part of the coronoid process preserved, as well as the second premolar and the first molar *in situ* (the second molar and the medial root of the third molar is beyond the mandible), alveoli of: the third molar, the first premolar, the second molar, all lost *post mortem*. The first molar demonstrates the 4th degree of wear and the second molar – the 3rd degree of wear.

On the basis of the preserved dentition, the presence of one individual aged 40–45 years was determined. Tooth measurements were not taken because of crowns' wear.

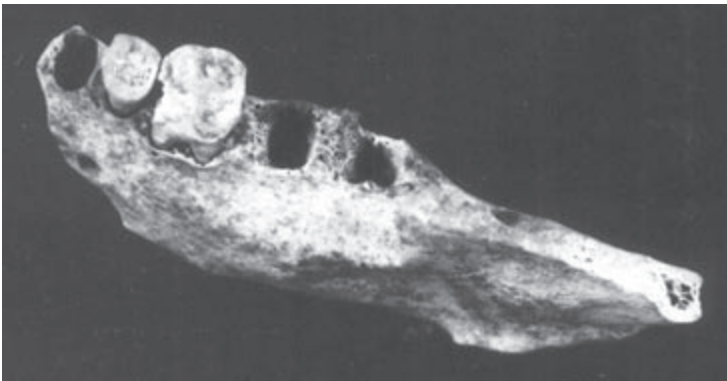


Fig. 58. NK/3402. Fragment of the mandible on the left side – with the second premolar and the first molar *in situ* and alveoli of the following teeth: the first premolar, the second and third molars, all lost *post mortem*.

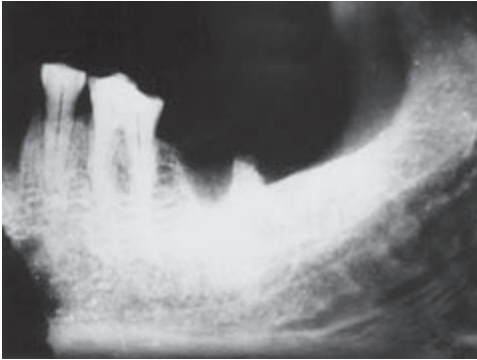


Fig. 59. NK/3402. Radiogram of the mandible on the left side from Figure 58.

NK/3403

In the grave NK/3403, 7 well preserved permanent teeth were found.

They are: the superior first premolar and the first molar on the left side, and the inferior ones: the central and lateral incisors, the canine, the second premolar and the second molar on the left side.

Apart from the well preserved permanent teeth, the following were found: a fragment of front mandible on the right side with heavily damaged alveoli of the left central incisor and the right teeth: both incisors and a two-root canine, all lost *post mortem*, and a fragment of a maxilla on the left side with preserved alveolus of the first premolar and the first molar, lost *post mortem*, and a damaged root of the second premolar fixed *in situ*. On the basis of the preserved dentition, the presence of one individual aged 45–50 years was determined.

Tooth measurements were not taken because of a considerable extent of crowns' wear.

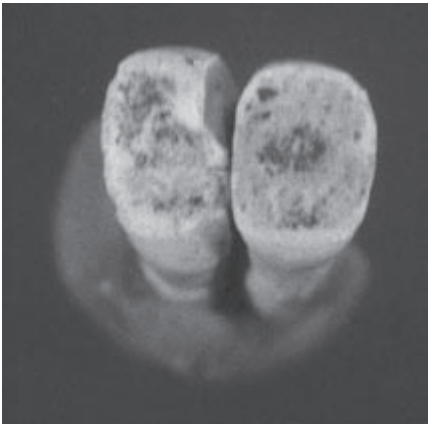


Fig. 60. NK/3403. Inferior left incisors, central and lateral one, with 4th degree of crown wear. Considerable wear of edges and interproximal surfaces is visible.

NK/3404

In the grave NK/3404, 6 well preserved deciduous teeth and 21 permanent teeth were found.

From the deciduous teeth the following are preserved: both superior canines, the left superior first molar and the second right one, and the inferior ones: the left first molar and the right second one. They demonstrate the 2nd degree of crown wear, while their roots are damaged.

From the permanent teeth, the following superior teeth on the right side are preserved: both incisors, the canine, both premolars and the first and the second molars. On the left side: the canine and the second premolar. Of the inferior teeth on the right side: the central incisor, the canine, both premolars and the first and second molars are preserved. On the left side: both incisors, the canine and both premolars. In the first inferior right molar the edge line of enamel reaches root bifurcation, on the buccal side a strongly marked foramen coecum is visible. In the second superior right molar a deep Carabelli's groove is visible.

Permanent teeth show different extent of root formation depending upon a tooth kind. In general, roots are heavily damaged. The first permanent molars and incisors have the 1st degree of crown wear.

Apart from this, the germ of the third inferior molar's crown on the right side is preserved.

On the basis of the number of described teeth, the presence of a child 8–9 years old was determined. The degree of formation of the third inferior molar's germ indicates the age of 10–11 years, which suggests presence of a second individual.

NK/3405

In the grave NK/3405, 6 permanent teeth, a fragment of maxilla and small fragments of crowns and tooth roots were found.

The fragment of maxilla on the right side has alveoli of the first molar and the second premolar, both lost *post mortem*. The preserved superior teeth on the right side are: the second premolar, the first and second molars; superior teeth on the left side: the central incisor, the lateral incisor, and the canine.

From the mentioned teeth the incisor, the canine and the second premolar are damaged; the incisor is in two fragments and the canine and the premolar have only crowns. The first and second molars demonstrate the 2nd degree of crown wear.

On the basis of the preserved dentition, the presence of one individual about 18–24 years old was determined.

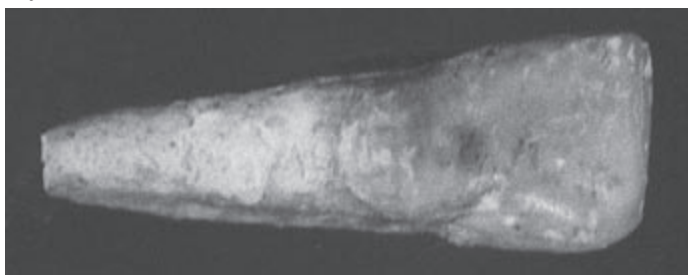

Fig. 61. NK/3405 Paracingular invagination on the superior left lateral incisor (lingual surface of tooth).

NK/3406

In the grave NK/3406, 27 well preserved permanent teeth, 6 deciduous teeth and small fragments of crowns and tooth roots were found.

From the deciduous teeth, the following are preserved: both superior canines, the right superior first molar, the left superior second molar and both inferior second molars. The molars demonstrate a considerable extent of wear – on most cusps dentine is exposed. The superior second molar has a four-cusp structure and both inferior second molars have a five-cusp structure. The first superior right molar has a medial buccal root broken, but visibly separated from the distal root with a damaged apical area. Both superior canines demonstrate wear of incisal ridge thus exposing dentine, whereas roots – initial period of resorption. The second superior molar has a three-root structure. A distal buccal and lingual root indicate beginning of resorption. The inferior second molars have two roots but their roots are damaged.

From the permanent teeth all are preserved except superior lateral incisors, the third molars and the first inferior premolar. The degree of root formation is varied and depends on a tooth kind. The formation of roots of the first superior and inferior incisors and the first molars is most advanced. The germs of the inferior third molars are least advanced in mineralization. The crowns of the first inferior molars demonstrate a six-cusp structure and a border line of enamel is lowered towards interradical space both on the labial and lingual sides. The inferior second molars have a four-cusp structure and the superior ones – three-cusp structure. The superior first molars have a cavity at the site of Carabelli's cusp. The superior first and inferior molars demonstrate the 1st degree of crown wear. On the inferior incisors, traces of calculus are visible, the calculus itself was damaged.

On the basis of the preserved teeth, the presence of one individual, a child 8–9 years old was determined.

NK/3411

In the grave NK/3411, 3 well preserved permanent inferior molars were found: the first and second right molars, well preserved, visibly darker in colour and with the 1st degree of crown wear and the first left molar, pale in colour demonstrating the 1st degree of wear in the area of a medial buccal cusp.

On the basis of preserved dentition, the presence of one individual aged 8–9 years was determined. Different colour and relief of chewing surfaces of both first inferior molars may indicate the presence of two individuals, similarly as a more advanced wear of the molar of a lighter colour.

NK/3412

In the grave NK/3412, 2 permanent teeth and 1 deciduous tooth were found.

Of the permanent teeth: the central superior incisor on the left side and the first inferior molar on the right side are preserved. The molar's crown dem-

onstrates the 2nd degree of wear. Of the deciduous teeth, the second superior molar on the left side is preserved. Its crown demonstrates the 1st degree of wear, its roots are formed, without traces of resorption.

On the basis of the preserved dentition, the presence of two individuals was determined – a child 4–5 years old and an adult 25–30 years old.

NK/3413

In the grave NK/3413, 4 permanent teeth, 1 germ of permanent tooth and fragments of crowns and tooth roots were found.

The preserved teeth are the superior teeth on the right side: the canine, the first and second premolars, the first molar and germ of the second molar's crown. The crowns of the second premolar and the first molar do not demonstrate wear, and their roots are damaged.

The crowns of the canine and the first premolar also do not demonstrate wear and their roots are formed to 1/2 height. Among small fragments of teeth, a fragment probably belonging to the second deciduous molar with a considerable crown wear was identified.

On the basis of the preserved dentition, the presence of one individual 9–10 years old was determined.

NK/3414

In the grave NK/3414, 3 permanent teeth were found. They are: the first and second inferior premolars, the first inferior molar, all on the right side. The molar's crown demonstrates the 4th degree of wear, and the crowns of both premolars – the 3rd degree.

On the basis of the preserved dentition, the presence of one individual aged about 34–40 years was determined. Tooth measurements were not taken due to advanced wear.

NK/3415

In the grave NK/3415, 10 permanent teeth, a fragment of mandible, two fragments of maxilla and small fragments of bones and teeth were found.

The fragment of mandible on the left side has the alveolus of the third molar and a part of the alveolus of the second molar, both lost *post mortem*. The fragment of maxilla on the right side has the first and second molars preserved *in situ*. The second fragment of maxilla on the right side has the first premolar preserved *in situ* and alveoli of the lateral incisor, the canine and the second premolar, all lost *post mortem*.

The remaining preserved inferior teeth are: the canine on the right side and the first molar on the left side. The superior teeth are: on the right side the lateral incisor, the canine, the first and second molars; on the left side the third molar. The inferior right canine from the neck to 1/3 of the crown's height has

linear enamel hypoplasia. The first superior left molar and the left superior canine and the inferior right canine have traces of calculus.

The superior first molars and the second superior molars demonstrate the 4th degree of wear, the superior third molar – the 1st degree of wear, the inferior first molar – the 1st degree.

On the basis of the preserved dentition, the presence of two individuals aged 20–24 years and 40–45 years was determined.

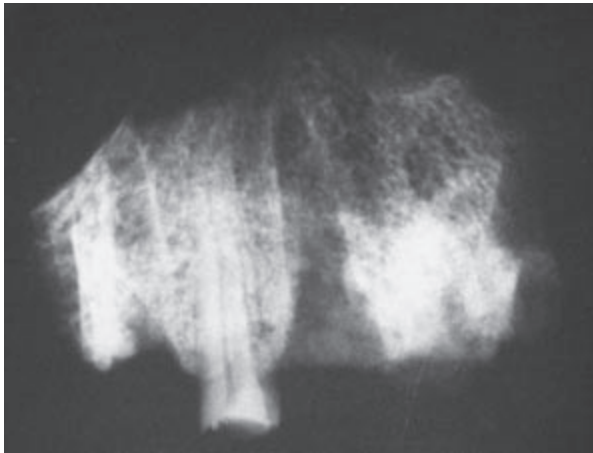


Fig. 62. NK/ 3415. Radiogram of maxilla's fragment on the right side with the first premolar *in situ*, alveoli of the canine and the lateral incisor lost *post mortem* and the root of the broken second premolar.

NK/3416

In the grave NK/3416, 5 well preserved permanent teeth, fragments of crowns and tooth roots, a fragment of mandible and a small fragment of bone were found.

The fragment of the mandible has 2 teeth preserved *in situ*. They are the second premolar and the first molar on the right side. Apart from this, both inferior third molars are preserved. The crowns of the premolar and the first molar demonstrate the 2nd degree of wear, and the third molars – the beginning of the 2nd degree. Among fragments of teeth, fragments of canines and premolars and a root of a molar, probably an inferior one, were identified.

Taking into account the number of preserved teeth and degree of their crowns' wear, the presence of an individual aged about 30–35 years was determined.

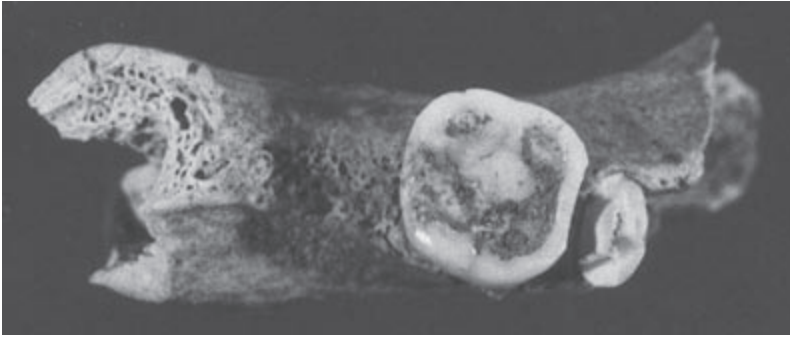


Fig. 63. NK/3416. Fragment of a mandible with damaged second premolar and the first molar *in situ*. The second molar is missing, whose alveolus underwent level atrophy.

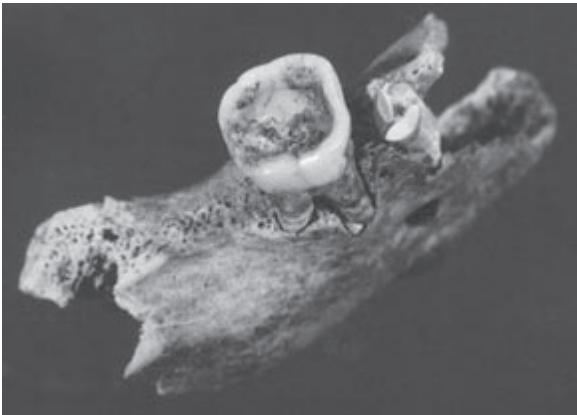
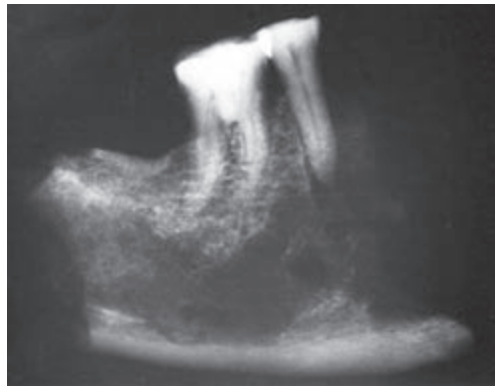


Fig. 64. NK/3416. Fragment of the mandible from Figure 63.

Fig. 65. NK/3416. Radiogram of the mandible from Figures 63 and 64. The texture of bony trabeculae at the site of the second molar indicates *ante mortem* tooth loss.



NK/3425

In the grave NK/3425, 6 permanent teeth, 1 permanent tooth root, a fragment of mandible, two fragments of maxilla and two small fragments of tooth roots were found.

The fragment of mandible's alveolar bone on the right side has the second premolar, the first and second molars and the root of the first premolar preserved *in situ*. The fragment of maxilla's alveolar bone on the right side has alveoli of the central incisor and the lateral one, the canine, the first and second premolars and the first and second molars, all lost *post mortem*. In the area of the first molar's roots, perforation of vestibular wall of the alveolar process is visible, which can be a trace after chronic bone inflammation (granuloma). The fragment of maxilla on the left side has: the canine, the first molar *in situ* and alveoli of the central incisor, the lateral incisor, the first and second premolars and partly the second molar, all lost *post mortem*.

Apart from the above-mentioned teeth, the second superior molar on the right side was preserved, whose roots fit to alveoli in the described fragment of the maxilla.

The first molars demonstrate the 4th degree of wear, the second inferior molar – the 3rd degree, and the second superior molar – the 2nd degree of crown wear.

On the basis of the preserved dentition, the presence of one individual about 45–58 years old was determined. Tooth measurements were not taken due to a considerable extent of crowns' wear.

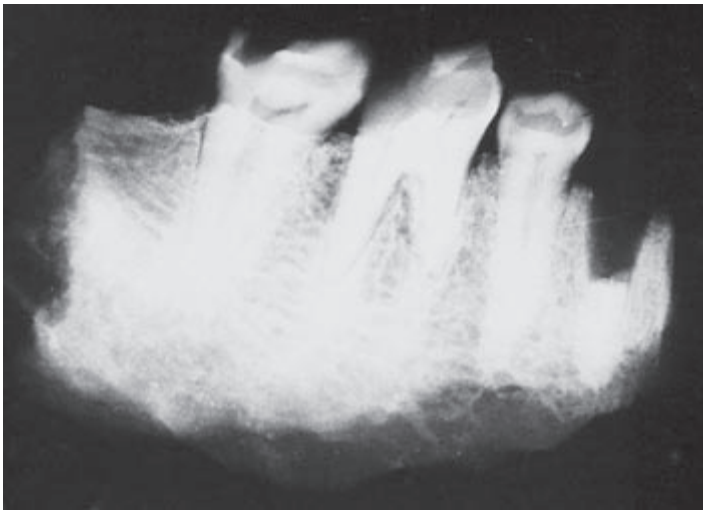

Fig. 66. NK/3425. Radiogram of a fragment of mandible's alveolar bone on the right side. The first premolar's root, the second premolar and the first and second molars *in situ* are visible. Agenesis of the third molar.

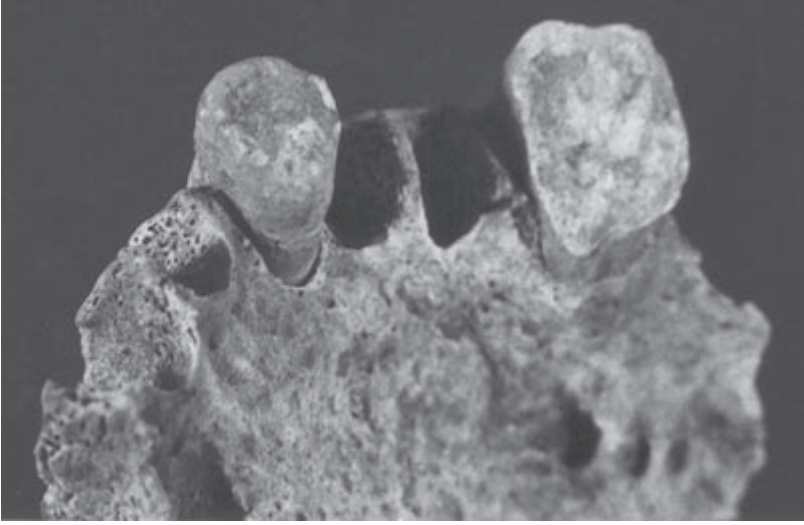


Fig. 67. NK/3425. Fragment of maxilla on the left side. The canine and the first molar show abrasion of chewing surfaces (*ad palatum*).

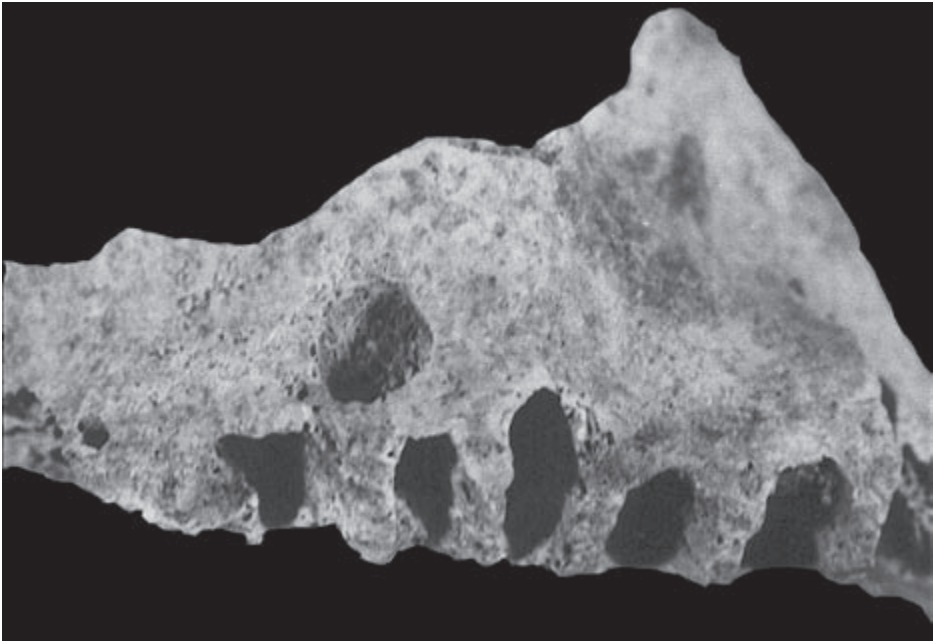


Fig. 68. NK/3425. Fragment of maxilla on the right side. An oval perforation of the vestibular surface of alveolar process at the level of the first molar's root is visible.

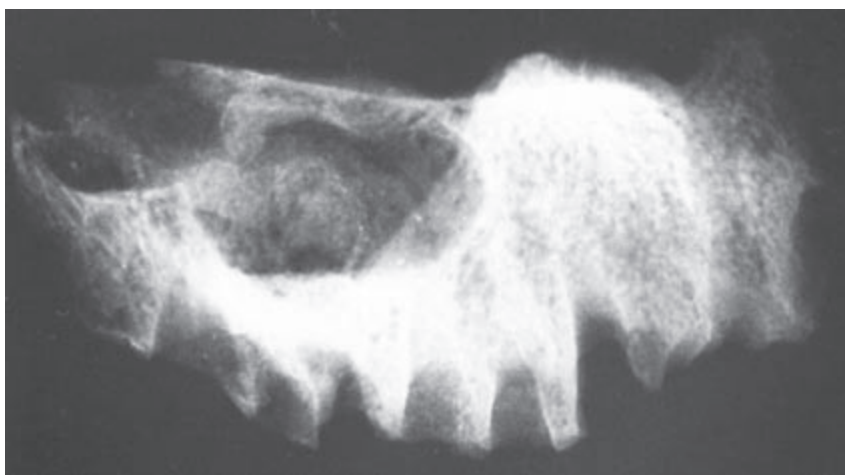


Fig. 69. NK/3425. Radiogram of the maxilla which is presented in **Figure 73**. Loss of bone tissue is caused by granuloma.

Tables

Table 1. Number of permanent teeth in the examined material.

Tooth type	I1	I2	C	P1	P2	M1	M2	M3
Maxilla	28	24	39	46	38	57	49	31
Mandible	34	29	34	45	61	73	64	33

Table 2. Number of deciduous teeth in the examined material.

Tooth type	i1	i2	c	m1	m2
Maxilla	—	—	5	5	9
Mandible	—	1	2	8	6

Table 3. Frequency distribution by the age at death.

Age in years	0–7	7–14	14–20	20–30	30–40	40–50	50–60	over 60
Number of individuals n=84	10	10	10	24	15	15	—	—

Table 4. Measurements of right superior permanent teeth ± 0.1 mm. MD – mesiodistal diameter, BL – buccolingual diameter.

Grave number	Estimated age of individual	I ¹		I ²		C		P ¹	
		MD	BL	MD	BL	MD	BL	MD	BL
1888	12–14							6.7	8.7
1890	18–24			6.4	6.4	8.5	9.0	7.5	9.4
2393	18–22			7.3	6.0	7.8	8.4	6.4	8.8
2395	11–12							7.5	9.4
2423	20–26			7.0	7.0	8.4	10.0	7.6	9.4
2437	11–12	9.6	7.7	8.2	6.6			7.3	9.3
2445	16–20	9.2	7.5					7.1	9.5
2511	14–15			7.8	6.7			7.8	10.7
2512	20–25							6.9	9.5
2547	20			7.1	6.5				
2627	25–30					8.1	8.2		
2638	26–30					8.5	8.6	—	9.0
2732	18–24	8.1	6.6			7.7	8.3		
3341	24–30	7.7	7.5	7.6	7.5			7.6	9.6
3352	24–30							6.7	9.0
3355	18–24			6.7	6.5				
3357	18–24							6.8	9.1
3361	18–20					7.5	7.2	7.0	8.9
3394	18–24					7.5	8.5	6.1	9.1
3401	30–35					7.5	8.2		
3404	8–9	9.8	8.0	7.5	7.0	8.5	8.9	7.7	9.6
3406	8–9	9.7	7.3			8.2	9.1	7.2	10.4
3413	9–10					8.4	9.3	7.0	9.6
3415	40–45					6.9	7.5		

Table 4. Continued.

Grave number	Estimated age of individual	P ²		M ¹		M ²		M ³	
		MD	BL	MD	BL	MD	BL	MD	BL
1888	12–14	6.9	8.9	11.2	13.0	9.3	11.4		
1890	18–24	7.5	9.8	10.9	12.5	10.4	12.3	9.5	11.5
2336	18–24					8.8	11.4		
2393	18–22			10.8	11.1				
2393	18–22	7.0	9.5	10.6	11.6	9.9	11.6	9.4	10.9
2395	11–12			11.6	12.0	10.4	12.0		
2423	20–26	7.4	9.8	10.6	12.4	10.4	11.9	9.7	12.0
2437	11–12	7.3	9.4						
2445	16–20	7.3	9.8	11.3	12.5	10.4	12.2		
2511	14–15	6.7	9.3	11.2	13.2	9.3	12.0	8.5	11.0
2512	20–25					9.3	11.3		
2638	26–30	6.9	9.1			9.6	12.7		
2639	30–36			11.1	12.8				
2732	18–24							9.8	9.9
2801	24–26	6.3	8.4					8.6	11.0
3341	20–24			10.0	11.5	9.6	11.5	8.2	10.8
3341	24–30	7.3	7.4	11.3	12.8	10.2	12.4	9.7	9.1
3345	20–25			10.7	12.2	9.8	11.5		
3352	24–30	6.4	9.0					7.2	10.9
3355	18–24					9.7	12.5	9.3	11.0
3372	24–28							10.1	13.1
3394	18–24	6.2	9.1	10.1	11.7	9.6	11.9		
3404	8–9	7.3	9.6	11.5	11.2	11.2	13.2		
3405	18–24	7.1	9.7	10.1	12.0	9.4	12.2		
3406	8–9	7.1	10.2	11.1	12.3	9.1	12.9		
3413	9–10	6.9	10.0	11.4	12.2				
3415	20–24							9.1	8.5

Table 5. Measurements of left superior permanent teeth ± 0.1 mm.

Grave number	Estimated age of individual	I ¹		I ²		C		P ¹	
		MD	BL	MD	BL	MD	BL	MD	BL
1888	12–14							6.9	9.2
1890	18–24			6.9	5.5	8.7	8.8	8.0	9.7
2393	18–22	8.2	7.1	7.0	6.4	7.8	8.2	6.4	8.7
2395	11–12					8.3	8.6		
2423	20–26					7.9	9.9	7.7	9.2
2437	11–12			7.9	6.8				
2445	16–20					8.2	8.5	7.3	9.6
2638	26–30	8.7	7.0						
2639	30–36	8.9	7.1						
2704	18–20							7.9	10.3
2732	18–24	8.2	6.5	7.7	6.0	7.8	8.3		
3341	24–30	8.2	8.5	7.0	7.5			7.5	9.6
3345	20–25	9.1	8.0						
3364	20–25					7.2	8.8		
3394	18–24	8.2	7.3					6.4	9.1
3404	8–9					8.4	8.7		
3405	18–24	9.1	8.2	7.2	6.4	8.0	9.8		
3406	8–9	9.6	7.3			8.1	9.1	7.2	10.3
3412	25–30	8.8	7.8						

Table 5. Continued.

Grave number	Estimated age of individual	P ²		M ¹		M ²		M ³	
		MD	BL	MD	BL	MD	BL	MD	BL
1888	12–14			11.4	12.7	9.8	10.0		
1890	18–24	7.5	9.6	11.4	12.5	10.7	12.3	9.0	11.5
2393	18–22	6.7	9.5	10.4	11.7	9.6	11.5	9.2	10.8
2423	20–26	7.3	9.7	11.8	11.4	9.5	12.2	9.6	12.4
2437	11–12	7.2	9.4						
2445	16–20	7.3	9.8	11.4	12.3	10.0	12.5		
2511	14–15			11.2	12.8			9.3	11.9
2512	20–25					9.7	11.4	8.4	11.8
2549	22–25							10.0	9.1
2634	18–20					9.3	11.4		
2638	26–30	6.8	9.0	10.2	11.6			9.9	11.9
2639	10–11			10.8	11.2				
2704	18–20					8.5	12.0		
2732	18–24					9.9	11.5	8.4	10.1
2801	24–26	6.6	8.9					8.5	10.6
3341	20–24			—	12.8	—	12.2	9.5	11.0
3341	24–30	7.5	10.4					10.7	10.2
3352	24–30			11.7	11.5	9.3	11.8		
3401	15–18			10.8	12.0				
3404	8–9	7.3	9.7						
3406	8–9	7.1	10.1	11.0	12.4	9.4	12.9		

Table 6. Measurements of right inferior permanent teeth ± 0.1 mm.

Grave number	Estimated age of individual	I ₁		I ₂		C		P ₁	
		MD	BL	MD	BL	MD	BL	MD	BL
1888	12–14							6.5	7.5
1890	18–24	6.3	6.0	6.3	6.3	8.0	8.2	7.5	8.2
2393	18–22	5.0	5.6	5.9	6.3	7.0	7.2	7.2	8.6
2395	11–12							8.1	8.4
2437	11–12	5.7	6.2	6.6	6.8			7.8	7.7
2445	16–20					7.4	8.2		
2511	14–15	6.0	6.4	6.5	7.2	6.9	7.9	7.2	7.3
2634	18–20					7.5	8.0		
2638	26–30	5.6	5.5	6.7	6.3			7.2	7.6
2724	15–18							7.5	8.5
2732	18–24	5.3	5.4	6.8	6.2	6.7	7.6		
2801	24–26	5.2	6.4	6.2	6.9	6.5	7.2	8.4	9.2
3341	24–30							7.8	8.9
3372	24–28							6.5	7.9
3404	8–9	5.6	6.4			7.5	8.0	7.4	8.1

Table 6. Continued.

Grave number	Estimated age of individual	P ₂		M ₁		M ₂		M ₃	
		MD	BL	MD	BL	MD	BL	MD	BL
1888	12–14	7.0	7.8	12.2	11.0	10.8	10.0		
1890	18–24	7.4	8.8	11.8	11.3	10.8	10.2	10.6	10.0
2335	30–36							11.0	10.7
2336	18–24	6.8	7.2			10.3	10.0		
2393	18–22					10.5	10.0		
2393	18–22	7.3	8.4	11.0	10.2	10.5	9.9		
2395	11–12			11.8	11.4	11.7	10.8		
2423	20–26	7.3	8.4						
2437	45–50	8.1	8.5						
2445	16–20	7.6	8.5	11.2	11.0	11.5	10.8	12.5	11.3
2511	14–15	7.8	8.7	12.7	11.1	11.6	10.5	10.3	9.9
2638	26–30	7.1	8.3	11.3	10.0	11.5	10.8		
2639	10–11			11.9	10.5	11.9	11.9		
2704	18–20			11.5	11.4	11.2	10.3	10.9	10.5
2724	15–18	7.9	9.3						
2732	18–24	6.9	7.7	10.5	10.0	10.3	9.1		
2801	24–26	8.4	9.2			10.3	9.6		
3341	24–30	7.6	8.9	11.8	11.4	10.2	10.4	10.6	10.2
3345	20–25	—	8.0						
3357	18–24					10.8	10.3		
3372	24–28							12.3	11.1
3394	18–24	6.5	8.0			10.8	11.0	10.3	9.5
3401	15–18			11.7	11.4	11.1	10.0		
3401	30–35	7.5	8.7						
3404	8–9	7.5	8.2	12.7	11.6	11.7	10.8		
3406	8–9	7.2	8.2	12.0	11.0	11.5	10.3		
3411	8–9			12.0	10.9	12.1	11.0		
3412	25–30			12.0	11.4				
3416	30–35							10.7	10.1

Table 7. Measurements of left inferior permanent teeth ± 0.1 mm.

Grave number	Estimated age of individual	I ₁		I ₂		C		P ₁	
		MD	BL	MD	BL	MD	BL	MD	BL
1888	12–14	5.3	5.9						
1890	18–24	5.8	6.4	5.4	6.5	7.9	8.5	7.4	8.2
2336	18–24					6.5	8.0	6.7	7.5
2393	18–22			5.8	6.3	7.0	7.8	7.2	8.6
2423	20–26			6.9	6.2	7.2	9.1	7.3	9.4
2437	11–12					6.9	8.1		
2445	16–20	5.5	6.0	6.2	6.0	7.5	8.2	7.8	8.3
2511	14–15	5.9	6.1	6.5	7.5			7.3	7.7
2512	20–25							6.8	8.3
2638	26–30			6.5	6.4	7.6	8.2	7.2	7.8
2732	18–24	5.6	5.7	6.6	6.3				
2764	20							7.4	8.4
2801	24–26							6.5	7.4
3341	24–30					7.3	8.9	7.0	7.9
3365	18–20							7.3	8.3
3394	18–24					6.5	8.0		
3404	8–9	5.6	6.1	6.9	6.4	7.4	7.9	7.2	8.0
3406	8–9	6.3	6.2	6.6	6.4	7.5	9.2		

Table 7. Continued.

Grave number	Estimated age of individual	P ₂		M ₁		M ₂		M ₃	
		MD	BL	MD	BL	MD	BL	MD	BL
1888	12–14			11.9	11.5	10.8	10.0		
1890	18–24	7.8	8.6	12.0	11.4	11.5	10.3	11.6	10.9
2336	18–24	6.0	7.4	10.0	10.8	9.6	10.0	9.4	9.1
2393	18–22	7.2	8.6			11.4	10.0	10.2	8.9
2393	18–22	7.3	8.3	11.1	10.1	10.5	10.0		
2395	11–12	7.9	8.3			11.4	10.5		
2423	20–26			10.8	11.4	11.2	10.3		
2445	16–20	7.6	8.2	11.4	11.3	11.4	10.5		
2511	14–15	7.9	8.7	12.8	11.1	11.3	10.7	10.1	10.0
2638	26–30	7.2	8.2	12.0	10.3	12.0	10.5		
2639	10–11			11.9	10.3				
2704	18–20			11.4	11.1	10.8	10.1	10.8	10.5
2732	18–24	5.0	7.5	10.9	9.9	10.3	9.2	9.9	8.6
2764	20					11.4	10.2		
2801	24–26			11.4	10.6			6.3	7.1
3341	24–30	7.2	8.0	11.5	11.0	11.0	10.2	10.1	10.2
3357	18–24							12.4	11.1
3365	18–20					10.6	10.2		
3394	18–24	6.7	8.2	10.6	10.7	10.8	9.6	11.0	9.5
3404	8–9	7.6	8.3						
3406	8–9	7.3	8.2	11.3	11.2	11.2	10.5		
3411	8–9			12.3	11.2				
3415	20–24			11.7	10.7				
3416	30–35							11.0	10.1

Table 8. Summary of measurements of permanent superior teeth: number of teeth, minimum value, maximum value, mean, standard deviation.

	I ¹		I ²		C		P ¹	
	MD	BL	MD	BL	MD	BL	MD	BL
n	16	16	15	15	23	23	26	26
min.	7.7	6.5	6.4	5.5	6.9	7.2	6.1	8.7
max.	9.8	8.5	8.2	7.5	8.7	10.0	8.0	10.7
mean	8.82	7.46	7.29	6.59	8.00	8.69	7.16	9.45
s.d.	0.66	0.55	0.49	0.54	0.46	0.67	0.52	0.52

	P ²		M ¹		M ²		M ³	
	MD	BL	MD	BL	MD	BL	MD	BL
n	26	26	29	29	29	29	23	23
min.	6.2	7.4	10.0	11.1	8.5	10.0	7.2	8.5
max.	7.5	10.4	11.8	13.2	11.2	13.2	10.7	13.1
mean	7.03	9.43	10.97	12.09	9.73	11.94	9.20	10.91
s.d.	0.37	0.62	0.51	0.59	0.58	0.64	0.77	1.09

Table 9. Summary of measurements of permanent inferior teeth: number of teeth, minimum value, maximum value, mean, standard deviation.

	I ₁		I ₂		C		P ₁	
	MD	BL	MD	BL	MD	BL	MD	BL
n	16	16	17	17	20	20	26	26
min.	5.0	5.4	5.4	6.0	6.5	7.2	6.5	7.2
max.	6.3	6.4	6.9	7.5	8.0	9.2	8.1	9.4
mean	5.68	6.04	6.41	6.51	7.23	8.17	7.21	8.06
s.d.	0.39	0.33	0.41	0.39	0.42	0.52	0.43	0.52

	P ₂		M ₁		M ₂		M ₃	
	MD	BL	MD	BL	MD	BL	MD	BL
n	30	30	33	33	37	37	20	20
min.	5.0	7.2	10.0	9.9	9.6	9.1	6.3	7.1
max.	8.4	9.3	12.8	11.6	12.1	11.9	12.5	11.3
mean	7.29	8.31	11.61	10.92	11.04	10.28	10.60	9.97
s.d.	0.65	0.48	0.64	0.50	0.58	0.51	1.31	1.00

Table 10. Measurements of right superior deciduous teeth ± 0.1 mm.

Grave number	Estimated age of individual	c		m ¹		m ²	
		MD	BL	MD	BL	MD	BL
2777	3					9.5	9.8
3345	4					9.3	10.0
3396	2			6.7	8.5		
3404	8-9	6.0	5.8			11.0	9.6
3406	8-9			9.9	7.4		

Table 11. Measurements of left superior deciduous teeth ± 0.1 mm.

Grave number	Estimated age of individual	c		m ¹		m ²	
		MD	BL	MD	BL	MD	BL
2639	8-9	7.0	6.4				
2777	3					10.1	9.8
3345	4			7.2	8.7	9.7	10.2
3352	3-4			7.0	8.8	9.3	10.2
3404	8-9	5.9	5.7	7.5	9.5		
3406	8-9	6.7	6.0			10.8	9.8
3412	4-5					9.9	10.5

Table 12. Measurements of right inferior deciduous teeth ± 0.1 mm.

Grave number	Estimated age of individual	m ₁		m ₂	
		MD	BL	MD	BL
2634	5	8.8	7.4	12.2	9.6
2639	8-9	8.7	6.9		
3349	3-4	8.2	7.3	10.4	9.0
3404	8-9			10.8	10.3
3406	8-9			10.8	9.5

Table 13. Measurements of left inferior deciduous teeth ± 0.1 mm.

Grave number	Estimated age of individual	m_1		m_2	
		MD	BL	MD	BL
2423	9–10			10.4	9.9
2639	8–9	8.9	6.8		
3349	3–4	8.1	7.3		
3404	8–9	8.6	8.7		
3406	8–9			10.7	9.6

Table 14. Summary of measurements of superior deciduous teeth.

	c		m^1		m^2	
	MD	BL	MD	BL	MD	BL
n	4	4	5	5	8	8
min.	5.9	5.7	6.7	7.4	9.3	9.6
max.	7.0	6.4	9.9	9.5	11.0	10.5
mean	6.40	5.98	7.66	8.58	9.95	9.99
s.d.	0.54	0.31	1.29	0.76	0.65	0.29

Table 15. Summary of measurements of inferior deciduous teeth.

	m_1		m_2	
	MD	BL	MD	BL
n	6	6	6	6
min.	8.1	6.8	10.4	9.0
max.	8.9	8.7	12.2	10.3
mean	8.55	7.40	10.88	9.65
s.d.	0.33	0.68	0.67	0.43

Bibliography

Brabant H.

1962: *Contribution à l'étude de la paleopatologie des dents et des maxillaires. La denture en Belgique à l'époque néolithique*, "Institut Royal des Sciences Naturelles Belgique" 38/6.

Brabant H., Kless L., Werelds R.J.

1958: *Anomalies, mutilations et tumeurs des dents humaines*, J. Prelat: Paris-Liège.

Goose D.H.

1963: *Dental Measurement: An Assessment of Its Value in Anthropological Studies*, [in:] „Dental Anthropology”, ed. D.R. Brothwell, New York, pp. 125–148.

Kozłowski S.K.

1990: *Nemrik 9. Pre-Pottery Neolithic Site in Iraq. General Report — Seasons 1985–1986*, Wydawnictwo Uniwersytetu Warszawskiego: Warszawa.

Murphy T.R.

1959: *Gradients of Dentine Exposure in Human Tooth Attrition*, "American Journal of Physical Anthropology" 17, pp. 179–185.

Philippas G., Appelbaum E.

1996: *Age Factor in Secondary Dentin Formation*, "Journal of Dental Research" 45, pp. 778–789.

Scott E.C.

1979: *Dental Wear Scoring Technique*, "American Journal of Physical Anthropology" 51, pp. 213–218.

Ubelaker D.H.

1978: *Human Skeletal Remains. Excavation, Analysis, Interpretation*, Chicago.