

# Hunters of Nemrik

Theya Molleson

Natural History Museum, London, UK

---

## Introduction

Nemrik lies on the southern edge of the Kurdish Mountains in the Tigris Valley. There is steppe in the immediate vicinity and deciduous forest in the nearby foothills. The early Neolithic settlement, dated to 10500–8400 BP, has been described by Kozłowski (1992, 2002). The burials in the houses were mostly single or double inhumations, which suggests that multiple burial as seen later at Abu Hureyra and Çatalhöyük was not practised. Most of the multiple burials include a juvenile (14/17). Conversely all, except three of the juveniles, were in multiple burials. From the density and demography it is likely that families used individual houses to bury their dead. Neonates and infants were disposed of elsewhere.

The burials into the floor of House 1A have been described by Borkowski (1992). The preservation was very poor so that neither numbers of individuals nor burial position could be determined. Two levels, I and II were recognized, and 11 graves were distinguished. In level I, concentration A, were long bones orientated N–S and two skulls; in concentration B were long bones along the wall of the house and a skull, also a flint sickle; concentration C comprised long bones orientated N–S and grinders. There were further graves in the stone pavements outside the house.

The faunal evidence indicates a hunting economy. An enormous amount of animal bone was recovered. It was all kitchen waste. Wild animals, especially antelope, predominated over domestic. The fauna comprises some sheep, cattle and pig but mainly antelope. Horse, deer, wild cattle, boar, beaver, badger, buffalo, jackal and panther are present. The people also hunted migrating geese, cranes, bustards as well as resident francolin, chukars and sandgrouse. The presence of birds of prey, notably the eagle owl, hint at falconry. Both bustards and crows, depicted among the sculptures, were well known to the inhabitants of the settlement (Lasota-Moskalewska 1994).

Agriculture as a subsistence seems to have been adopted during the late phase c. 9500–9000 BP and grinding stones, rubbers, mortars and pestles are

then part of the lithic assemblage. The range of artifacts includes grindstone, polishing plates, awls, bone needles, a whetstone, pounders, shaft straighteners and bolas stones (Kozłowski and Aurenche 2005). The subsistence technology can be, to some extent, inferred from the artifacts for pounding grain (mortars), rather than grinding. No pottery has been recorded. The technique of hunting is less clear. There are bolas stones, but few 'spear' straighteners. Arrow heads are exceptional and exotic, occurring only in some burials.

## The human bones

The form of the human bones from Nemrik 9 might shed some light on the hunting habits of the people. The bones are characterised by a number of features not often seen at other sites of the same general period and by the absence of a number of features that are observed elsewhere.

Bones from 101 contexts were examined. A few contexts proved to have the remains of more than one individual and bones that were probably intrusive were noted in a few assemblages. The partial remains of up to 120 individuals were noted. All parts of the skeleton are represented although recovery was poor. The bones of the hand, foot, and knee, which can be expected to survive well, are under-represented and fragile bones of the spine, scapula and hip have only rarely been recovered, while the loss of practically all joint surfaces is most regretted. The poor recovery severely limits interpretation of both mortuary practices and demography. For example, any evidence for separation of the cranium from the post-cranial skeleton is circumstantial.

Physically the bones are large, especially the lower limb, with, in general, good cortical bone. Although large the bones are gracile rather than robust, without marked muscular development or entheses.

Age and sex was difficult to assess. Adults and juveniles of both sexes are certainly represented, while infants and newborn are not, with the possible exception of one infant femur in context 3409. With infants excluded the proportion of immature individuals to adults (c. 27:89) is therefore not unexpected for a (preindustrial) domestic assemblage (Bocquet and Masset 1977).

Estimation of age at death has not been attempted, since the traits used for ageing were generally not preserved. It was noted, however, that there was little evidence for osteo-arthritis or other degenerative conditions and that cranial suture closure appeared to be slower than in modern populations as has been suspected at Çatalhöyük (Molleson et al. 2005). Rates of ageing may have differed in the past, when people were physically much more active than they are today. The marks of muscle attachments on the bones were noted but the intensity was not scored since this has been shown to correlate with age and sex (Weiss 2004); factors that could not be reliably assessed on the Nemrik material.

Cranial fragments only, excluding the mandible, were noted in 47 instances, post-cranial bones only were identified in 51 cases and all parts in the remaining 49 contexts. No cut-marks were noted. The skull in one context (2513) was burnt. Many bones had superficial post-deposition dark staining but whether

this was a consequence of secondary disturbance of the grave would need to have been observed at the time of excavation. There was a hard grey concretion deposit on the surface of many of the bones, which had been laboriously removed by picking and scraping. The concretion is presumably an evaporite deposit associated with flooding and drying of the burial place. There was no sign of ochre or other coloured mineral staining the bones.

Although no hyoid bones were noted, the scapula and patella only occasionally, the fairly frequent presence of the bones of the hand and foot suggests that excarnation was not practised and that in general these were primary burials. Most were single inhumations or double burials of adult and juvenile. There is little evidence for mixing of skeletons through disturbance of earlier graves. Just a few (four) probably intrusive bones were noted.

The bones will be described first in anatomical sequence, and then I shall try to draw together the evidence for activity and lifestyle that they display.

### Summary description of the material

Cranial fragments were identified in half the contexts (60 out of 120), but a mandible fragment was found in only thirteen of these; mandible fragments alone were found in a further five contexts. Both male and female adults and juveniles are represented. No cranial fragments were noted in 51 contexts, which raised the question that crania could have been separated from the rest of the body at some stage in the burial process. Skull fragments without post cranial bones occurred in 16 contexts. Metopism was identified in two crania and arachnoid depressions in three. Most of the crania had open sutures, in two cases where arachnoid depressions were present. No clustering of traits was found. Extrasutural wormian bones were noted in one individual (2802).

A broad shallow depression across the top of the skull of 2628 and 3415 suggests that loads may also have been carried from a 'tump-line' over the head (**Fig. 1**).

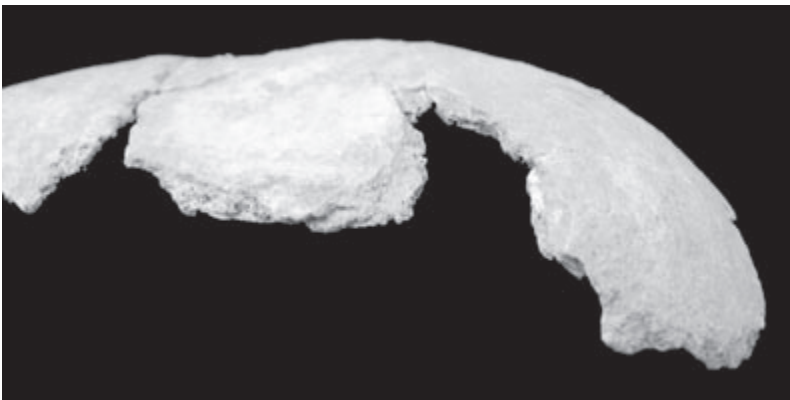


Fig. 1. Cranial vault fragment with transverse sulcus behind the coronal suture.  
Nemrik 9, Gr. 1, house 19, sk 3415.

The teeth occasionally show considerable abrasive wear but less than compared to Abu Hureyra, Jericho or Jarmo where hard cereal grains were part of the diet and where teeth were used to perform tasks, and the dentine is often worn below the enamel. There is little caries and calculus is slight. No hypercementosis, fractures or chipped teeth were observed. The roots of the teeth are stained brown. The relatively moderate wear of the teeth suggests a diet largely free of large cereal grains that are hard and abrasive (Fig. 2).

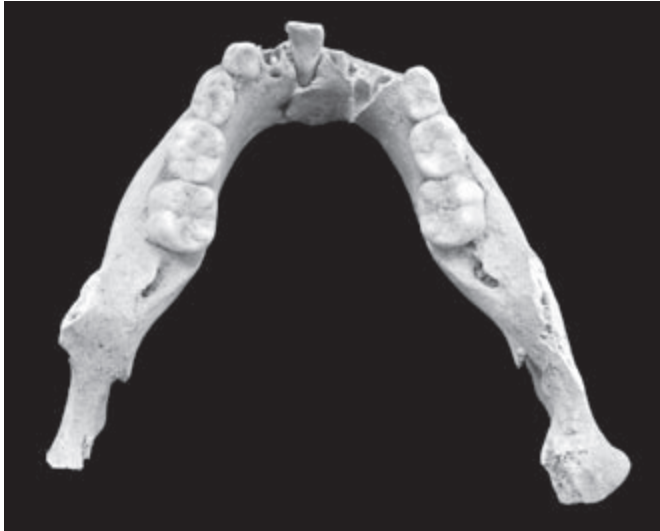

Fig. 2. Mandible of a 5-6 year old individual showing only slight abrasion of the deciduous teeth. Gr. 39, house 2A, sk 2802.

There is evidence that strong protrusive forces were used in sk 3356; resulting in forward expansion of the coronoid process which has a double edge where the temporalis muscle attaches. This is characteristic of the cord makers identified at Abu Hureyra (Molleson 2006). Unfortunately, further evidence for task related wear is lacking, since both the mandibular condyle and the front teeth of sk 3356 are missing (Fig. 3, 4).

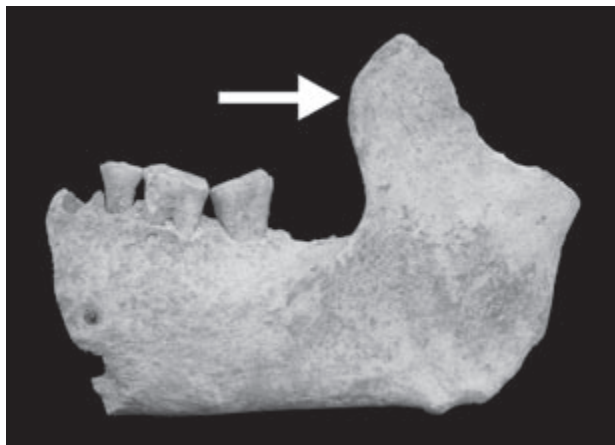

Fig. 3. Mandible with anterior development of the coronoid process and uneven abrasion of the molar teeth. Sk 3356.

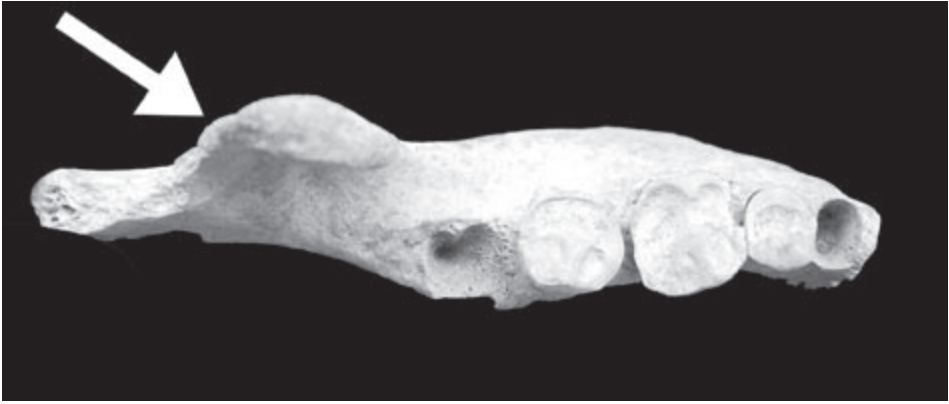

Fig. 4. Occlusal view of mandible showing double edge of the coronoid process and relatively severe wear on the teeth. Sk 3356.

Strong muscle imprints on the clavicles of sk 2133, 3402, 3406 and 3355 suggest specific stresses involving the extension and lateral rotation of the arm – perhaps arm swinging to pound with a pestle seeds in a mortar. To achieve this the pectoral girdle (shoulder) must be stabilised (involving the subclavius muscle, which inserts in a groove on the inferior surface of the clavicle. The imprint of the costoclavicular ligament at the medial end of the clavicle in sk 3402 is very large. This ligament stabilizes the clavicle especially when heavy loads are carried on the back. Evidence for load bearing is also seen on the humerus of this individual (Fig. 5).

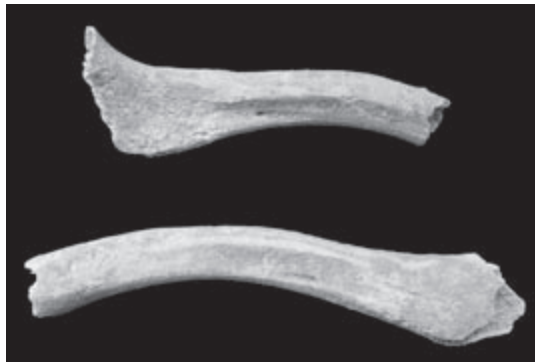


Fig. 5. Fragments of right and left clavicles with long deep insertion areas for the subclavius muscles. Gr. 8, sk 2133.

The Nemrik humerus seems to be a relatively gracile bone compared to the femur. The mid-shaft section is often D-shaped in both large and small bones (male and female?) and the septum of the supracondylar fossa can be perforated. The deltoid tuberosity can be quite well developed and the lateral border well developed. The presence of a supracondylar radial imprint in sk 3402 could be associated with carrying a load slung over the shoulder so that the elbow is strongly flexed and the head of the radius impinged on the distal end of the humerus (Fig. 6).

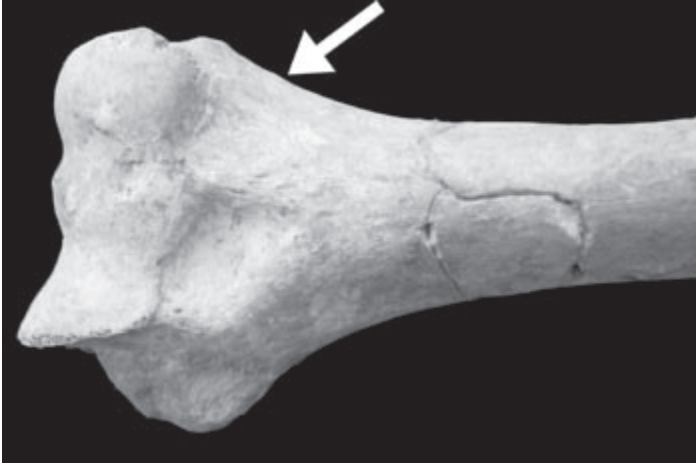


Fig. 6. Distal end of left humerus with shallow radial fossa beside the deeper coronoid fossa. House 8A, sk 3402.

A strongly developed lateral supracondylar ridge on the lateral side of the elbow of sk 3394 indicates that the extensor carpi radialis longus and brachioradialis were well-developed muscles as well as strong deltoid muscles (Fig. 7). Asymmetry of the humeri of sk 3394 could result from some handed activity or simply a habit of carrying loads over one shoulder.

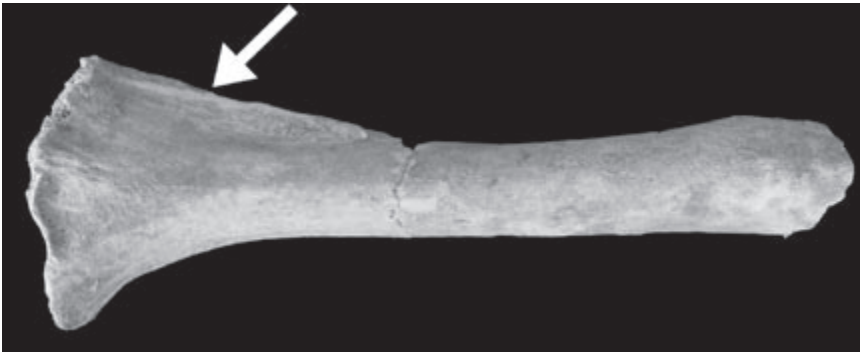




Fig. 7. Right humerus shaft with strongly developed lateral supracondylar ridge. House 4A, sk 3394.

There is little evidence for handed tasks. Only 2133 showed marked asymmetry of the clavicles (Fig. 5). A pronounced supinator crest of the ulna, which is developed in spear throwers, was observed in sk 3363 but in the left (right missing), which suggests some other activity. In context 1891, which has a major enthesis of the attachment area of gluteus maximus on the femur, the deltoid tuberosities of both humeri are also well developed. The deltoid muscle raises the arm above the shoulder and would be active during use of bolas stones or even of a pestle.

The femur can be rather bowed and buttressed by a strong linea aspera (eg. 3421 both left and right). This could arise from habitually kneeling to perform some task like pounding grain in a mortar. The buttressing is much less marked

than in the bones from Abu Hureyra where it is associated with the use of a saddle quern to grind grain (Molleson 1994). The gluteal sulcus is sometimes but not always associated with stronger than usual linea aspera and hence developed adductor muscles. Gluteus maximus and adductor magnus muscles produce adduction of the thigh and extension of the hip.



Figs. 8 and 9. Enlarged development of the hypotrochanteric fossa in two femur shafts. Sk 3421a (above), sk 3421b (below).

The area of attachment for the gluteal muscles (gluteus maximus) on the lateral femur below the trochanter was typically an extremely pronounced deep sulcus even in young individuals (eg. 1891, 2437, 2635). That it could be related to sitting cross-legged as the habitual position of rest was considered but the fovea in the femoral head, when observed (3419), was not pronounced. The hypotrochanteric fossa where the gluteus maximus attaches on the femur was often long and deep (Fig. 8 and 9). Gluteus maximus is important in running and jumping more so than in walking. It would develop as a powerful muscle in those who had to run down an animal, whether it was to be taken live or killed. Gluteus maximus is a major extensor of the thigh especially when the thigh is flexed as in rising from a forward flexed position and in climbing and running when the thigh is thrust posteriorly (backwards).

In sitting cross-legged (the sartorial squatting position) lateral rotation of the femur is combined with abduction and flexion exceeding 90 degrees. Gluteus maximus produces lateral rotation of the femur. Lateral rotation can result that



the two legs are parallel and horizontal – the “lotus” position (Molleson 2007). The range of rotation depends on the angle of ante-version of the femoral neck, which is usually quite wide in the child. This leads to medial rotation of the thigh and the walking child displays a bilateral genu valgum. This wide angle of ante-version can be maintained and even increased when children become accustomed to sitting on the ground with their heels pressed against each other and their hips flexed. This posture causes medial rotation of the femur and accentuates the angle of ante-version as a result of the greater plasticity of the young skeleton (Kapandji 1987: 12).

Evidence for other squatting positions was limited due to the poor preservation of the articular surfaces. Context 3345 has a rolled articulation of the head of the tibia and 3425 has a squatting facet on the distal tibia. Squatting facets of the hip, knee, ankle or toe could not be observed. A small vastus notch on the patella was noted in a third (2627, 3349, 3425, ie. 3/9) suggesting that squatting on the heels could be a position of rest, although the vastus notch could also be induced by the sartorial position (Fig. 10).

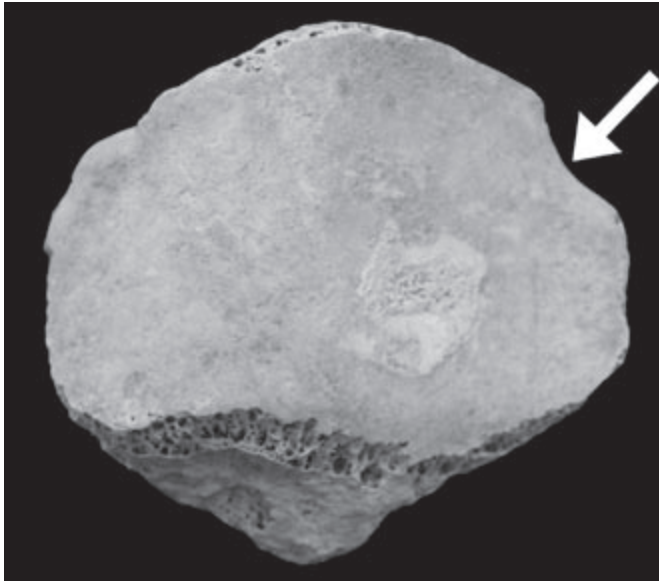


Fig. 10. Posterior surface of right patella showing a small vastus notch on the upper lateral border and an area of pressure plaque on the articular surface. House 8A, sk 3425.

The Nemrik tibia is invariably strongly platycnemic and, where it could be observed, the articulation with the fibula, which is a relatively robust bone, is well developed indicating that the fibula was a weight bearing bone, adapted to locomotion over uneven terrain. Tibias from Abu Hureyra are also platycnemic and it is possible the side-to-side flattening of the shin bone results from enlargement of the calf muscles used in running and walking, especially where shoes are not worn. The side-to-side flattening of the tibia would allow large flexor muscles of the ankle, which attach between the tibia and fibula, to be accommodated (Lovejoy et al. 1976). On this point Lovejoy et al. concluded



that “only when anterior-posterior and torsional strains were substantially increased over those in the coronal plane, would the tibia systematically respond by differential adaptation to these specific modes and with subsequent sacrifice of strength in the medio-lateral plane. Considering the paramount role of the soleus, gastrocnemius and other posterior shank muscles in locomotion and the acute torsional strains likely to occur in active locomotion on uneven substrates this hypothesis does not seem improbable.”

There is usually a facet on the base of the first metatarsal where it articulates with the second metatarsal; this is often absent in those who wear shoes (Fig. 11). Extended articulation of the head of the first metatarsal (MTI) was not common and only weakly developed in a few cases (3363, 3400) indicating that it was not a habit to kneel with the toes curled under, and by implication a saddle quern was not used to grind grain (Molleson 1989).

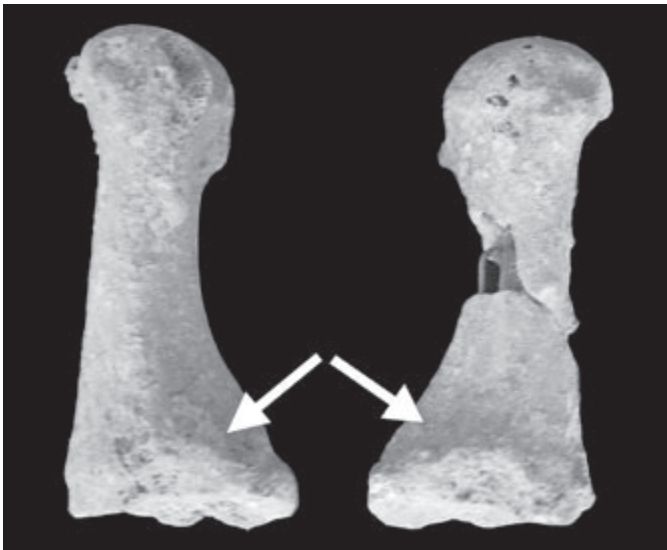


Fig. 11. Right and left first metatarsals of the foot. Each has a facet on the lateral border of the base for articulation with metatarsal II. Sk 3363.

Pounding to prepare wild cereals could have been undertaken from several positions, sitting or standing. The big toes of 3363 and 3400 have a “kneeling tubercle” on the medial side, perhaps associated with curling the toes backwards (Fig. 12).

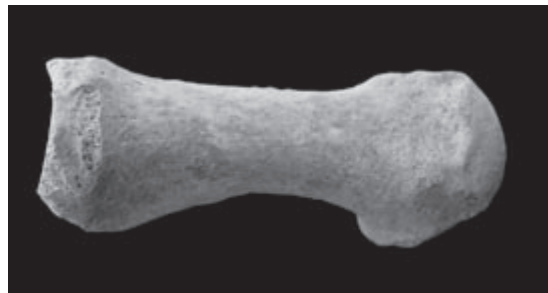

Fig. 12. Left metatarsal I with normal development of the articular area of the head and well developed medial tubercle. Gr. 7, sk 3400.

The epiphyses of the proximal phalanges of the foot are usually wedged confirming, unsurprisingly, that shoes were not worn (eg. 3345, 1889, 3401).

Pathologies were infrequent, healed, and most are the consequence of injury or ageing processes. However, few vertebrae could be examined. Context 2352 had a healed fracture of a metacarpal (hand) bone. Periosteitis or myositis of the lower leg bones (3402, 3345, 3357) and 3416 of the radius suggest soft tissue injuries. Context 3425 has a large cyst in the calcaneus, probably an implantation cyst, a response to a foreign body (**Fig. 13**).

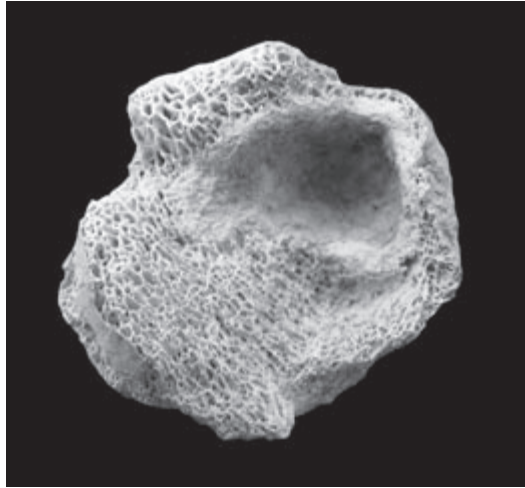


Fig. 13. Fragment of calcaneus showing probable implantation cyst. House 8A, sk 3425.

Sk 2085 has slight development of osteophytes around the proximal articulation of the first metacarpal (MCI) and the distal articulation is extended.

The mental tubercles of a mandible fragment from Gr. 38 (sk 2628) for the tongue are greatly enlarged. The genioglossus muscles arise from the upper mental spine of the mandible and into the tongue. They protrude the tongue (Hamilton 1976: 346, Fig. 452). The geniohyoid is attached to the inferior genial tubercle of the mandible and to the body of the hyoid. It helps to open the mouth against resistance if the hyoid bone is fixed. If the mandible is fixed it can pull the hyoid bone upwards and forwards (Hamilton 1976: 161, Fig. 86).

There was no unequivocal evidence for combat injuries, although exotic arrowheads were found associated with a suspiciously large number of burials, including in the skull from burial 39, in the pelvis area of burial 5, and next to the arm of burial 33 (Kozłowski 2002: 40).



Fig. 14. Fragment of chin area of mandible showing enlarged mental spines on the inner surface. Gr. 38, house 1A, sk 2628.

## Discussion

The most striking feature of the human bones from Nemrik is the development of the hypotrochanteric fossa on the femora of young and old. There must have been an enormous development of gluteus maximus muscles on the thighs. The general lack of any marked development of supinator crest on the ulna is also notable and suggests that hunting with spears was not important. Also the lack of kneeling articulations on the foot bones suggests that grinding of plant grains to make flour was not done to any great extent.

People are individuals and each is unique in the way even a repetitive task is carried out but sometimes patterns can be discerned. At Nemrik the frequent development of the gluteal and adductor muscles is impressive and suggests that vigorous running over uneven terrain was an important part of life for some – perhaps running down the hunt. (San Bushmen have been known to chase a quarry for three or four days until the animal is worn out). The gluteal depression was observed both in large femora, which could be male and in small femora which could be female and also, particularly, in adolescents. The marked platycnemia of the tibia seems also to be a response to development of the muscles of the anterior extensor and posterior flexor compartments of the leg. The enlargement of the muscles of the shin and the calf, which are important in running and walking, puts pressure on the lateral side of the tibia. If this happens, together with torsional stresses during growth, the tibia becomes flattened from side to side or platycnemic.

Dimorphism between the sexes was difficult to assess. Although there does seem to have been a size difference with men quite a bit larger than women there isn't evidence for behavioural differences between the two sexes. Hunting requires long-distance travel and running. Subsistence patterns based on high levels of mobility are generally associated with high levels of sexual dimorphism in lower limb strength (Larsen et al. 1995; Holt 2003). Hunting or herding requires co-operation and can be a better solution to the problem of providing daily food than the larger foraging trips required to compensate for local resource depletion (Lieberman 1993: 611).

Nemrik seems to have been a hunting or wild animal based economy, with speed in running important as indicated by the anatomy of the leg bones. This interpretation is compatible with the artifact and faunal evidence. Mazurowski (1997: 163) noted an increase in bolas balls as evidence for a sudden increase in hunting activities. When bolas stones are used to ensnare prey the animal has to be approached within range of the missile. Arrowheads are rare in the lithics and so called shaft straighteners are only present in the lower levels (Kozłowski 1999: 113), which imply that neither bows and arrows nor spears were much used for hunting. Lasota-Moskalewska (1994) noted that some animal phalanges were modified to form whistles and estimated that the sound would have carried for a kilometre or so. These could have been used by hunters to communicate between themselves or to attract birds.

## Summary

At Nemrik human bone evidence suggests that in hunting animals may have been run down by the hunters.

The physique of the human skeletons supports the lithic evidence presented by (Mazurowski 1997: 163). An increase in the numbers of bolas balls in Phase IV–V (7000–6000 BC) implies a sudden increase in hunting activities (or in catching live animals for domestication). Young animals might have been taken live during hunting expeditions for domestication. Further, the lack of strong pronator attachment areas on the forearms or of kneeling facets on the toes supports Mazurowski's (1997: 187) point that, in the absence of pounders and mortars in houses throughout the period, crushing fruits and seeds into groats concluded the food processing. Cause of death cannot usually be ascertained but the association of arrowheads with the bones of several skeletons is suspicious (Wiercińska 1999: 40).

## Acknowledgements

My sincere thanks to Professor Alina Wiercińska for the opportunity to study the human bones from Nemrik that are stored in the Department of Anthropology, State Archaeological Museum, Warsaw, Poland. I am most grateful to Basil Shepstone for commenting on the pathologies, to Arkadiusz Sołtysiak for providing the photographs and to Veronica Hunt for help with translation.

## Bibliography

### **Bocquet J.-P. and Masset C.**

1977: *Estimateurs en paléodémographie*, "L'Homme" 17, pp. 65–90.

### **Borkowski W.**

1992: *House No 1/IA/IB*, [in:] "Nemrik 9. Pre-pottery Neolithic Site in Iraq. Vol. 2", S.K. Kozłowski (ed). Wydawnictwa Uniwersytetu Warszawskiego, Warsaw, pp. 35–42.

### **Hamilton W.J.**

1976: *Textbook of Human Anatomy*. 2<sup>nd</sup> edition, Macmillan Press, London.

### **Holt B.M.**

2003: *Mobility in Upper Palaeolithic and Mesolithic Europe: Evidence from the Lower limb*, "American Journal of Physical Anthropology" 122, pp. 200–215.

### **Kapandji I.A.**

1987: *The Physiology of the Joints*, vol. 3, 2<sup>nd</sup> edition, Churchill Livingstone, London.

### **Kozłowski S.K.**

1992: *Nemrik 9. Pre-pottery Neolithic Site in Iraq, Vol. 2: House No 1/IA/IB*, Wydawnictwa Uniwersytetu Warszawskiego, Warsaw, pp. 137.

1999: *The Eastern Wing of the Fertile Crescent*, "BAR Intern. Series" 760, Oxford, pp. 194.

2002: *Nemrik: an Aceramic Village in Northern Iraq*, Institute of Archaeology, Warsaw University, Warsaw, pp. 117.

### **Kozłowski S.K. and Aurenche O.**

2005: *Territories, Boundaries and Cultures in the Neolithic Near East*, "BAR Intern. Series" 1362, Oxford, pp. 275.

### **Lasota-Moskalewska A.**

1994: *Nemrik 9 Pre-pottery Neolithic Site in Iraq, Vol. 4: Animal Remains*, Wydawnictwa Uniwersytetu Warszawskiego, Warsaw, pp. 63.

### **Lieberman D.E.**

1993: *The Rise and Fall of Seasonal Mobility Among Hunter-Gatherers*. "Current Anthropology" 34, pp. 599–631.

### **Lovejoy C.O., Burstein A.H. and Heiple K.G.**

1976: *The Biomechanical Analysis of Bone Strength: A Method and Its Application to Platycnemia*, "American Journal of Physical Anthropology" 44, pp. 489–506.

### **Mazurowski R.F.**

1997: *Nemrik 9. Ground and Pecked Stone Industry in the Pre-Pottery Neolithic of Northern Iraq*, Warsaw, pp. 214.

### **Molleson T.**

1989: *Seed Preparation in the Mesolithic: the Osteological Evidence*. "Antiquity" 63, pp. 356–362.

1994: *The Eloquent Bones of abu Hureyra*. "Scientific American" 271, pp. 70–75.

2000: *The People of abu Hureyra*, [in:] A.M.T. Moore, G.C. Hillman, and A.L. Legge (eds), "Village on the Euphrates. From Foraging to Farming", Oxford University Press, pp. 585.

2006: *The Third Hand: Neolithic Basket Makers of Abu Hureyra*, [in:] "Proceedings of the 13th International Symposium on Dental Morphology, Łódź (2005)", pp. 233–243.

2007: *Working Bones* [in:] S. Hamilton, R. Whitehouse and K. Wright (eds), "Women in Archaeology", Institute of Archaeology, London.

**Molleson T., Andrews P. and Boz B.**

2005: *Chapter 12: Reconstruction of the Neolithic People of Çatalhöyük*, [in:] I. Hodder (ed.), "Inhabiting Çatalhöyük: reports from the 1995–1999 Seasons. Çatalhöyük Research Project", vol. 4, McDonald Institute Monographs, British Institute of Archaeology at Ankara, pp. 279–300.

**Weiss E.**

2004: *Understanding Muscle Markers: Lower Limb*, "American Journal of Physical Anthropology" 125, pp. 232–238.

**Wiercińska A.**

1999: *The Odonto-Anthropological Analysis of the Human Remains from the Preceramic Site at Nemrik (Iraq)*, [in:] "IVth Intern. Anthrop. Congr. Aleš Hrdlička 'World Anthropology at the Turn of the Centuries'", Prague.